

Letter to the Editor

Cite this article: Parasher G, Yadav BK, and Kar SK (2024). Electroconvulsive therapy: a last resort for lorazepam-resistant catatonia in patient with large arachnoid cyst. *CNS Spectrums* 29(2), 83–84.
<https://doi.org/10.1017/S109285292300634X>

Received: 13 September 2023
 Accepted: 16 October 2023


Keywords:

Electroconvulsive therapy; catatonia; lorazepam; schizophrenia; arachnoid cyst

Corresponding author:

Sujita K. Kar;
 Email: drsujita@gmail.com

Electroconvulsive therapy: a last resort for lorazepam-resistant catatonia in patient with large arachnoid cyst

Gunjan Parasher¹, Brijesh K. Yadav² and Sujita K. Kar² 

¹Faculty of Medical Sciences, King George's Medical University, Lucknow, India and ²Department of Psychiatry, King George's Medical University, Lucknow, India

To the Editor,

Intracranial space-occupying lesions may present with a spectrum of neuro-behavioral manifestations. Sometimes, the lesions are incidentally reported during neuroimaging, indicating that the person may remain asymptomatic despite having a space-occupying lesion. Arachnoid cyst is one such intracranial space-occupying lesion that can present with psychiatric manifestations like—catatonia.^{1–3} Arachnoid cysts are primarily benign lesions and are often detected accidentally.⁴ We report here a young man with lorazepam nonresponsive catatonic schizophrenia with an arachnoid cyst, who was treated with electroconvulsive therapy (ECT) safely and needed maintenance ECT due to reemergence of catatonic symptoms following discontinuation of ECT after acute management of catatonia

A 20-year-old male was brought in for psychiatric consultation by his family due to concerning symptoms. These included aimless wandering, mutism, holding odd and inappropriate postures, unprovoked violent behavior, holding food and saliva in the mouth for extended periods, and poor self-care. The patient's older brother reported that he appeared to be asymptomatic and well-adjusted in his social, personal, and professional life 2 years prior. However, his behavior began to change with reduced sleep, inappropriate smiling, and disorganized behavior. His previously cheerful personality became irritable, and he became less active in family activities. Over time, his irritability increased, leading to physical altercations and damage to household belongings. The patient was brought for psychiatric consultation one and a half years ago but refused to take prescribed medications, absconding from home for over 16 months. He was later found in a disheveled state and brought back home. The patient spent most of his day in solitude, showing odd behavior such as inappropriate facial expressions and postures and staring at objects for hours. Family members attempted to feed him, but he would resist and keep food in his mouth for hours. Initially, the family sought faith-based healing, but seeing no improvement, they ultimately decided to seek psychiatric consultation. The patient's past and family history were uneventful, and there was no evidence of maladaptive personality traits in his pre-morbid state

During the initial phase of his illness, the patient was investigated and magnetic resonance imaging (MRI) of the brain was done, which revealed a large arachnoid cyst in the posterior fossa (presence of bilateral arachnoid cysts located behind the cerebellar hemispheres, measuring 30 × 47 × 34 mm on the right side and 26 × 33 × 34 mm on the left side; [Figure 1](#)); however, there was no mass effect. Neurosurgery consultation at that time recommended no active intervention, considering it as an incidental finding, as there were no neurological deficits on examination. Fundoscopic examination of the patient was insignificant clinically

During the consultation, a comprehensive evaluation was conducted on the patient. As a result, the patient was diagnosed with catatonic schizophrenia and prescribed appropriate treatment. Initially, the patient was given a 4 mg lorazepam injection, which showed positive results in improving mutism, rigidity, and posturing. To maintain progress, the patient was prescribed a daily regimen of 10 mg olanzapine tablets at bedtime and 6 mg lorazepam per day, given in divided doses. In addition, the patient was given a 20 mg depot antipsychotic, flupenthixol, due to a history of nonadherence and absconding tendencies. Despite minimal improvement, the dose of lorazepam was increased to 16 mg/day and zolpidem was added at a dose of 30 mg/day. The patient's baseline Bush Fransis Catatonia Rating Scale (BFCRS) score was 12, which improved to 9 after the lorazepam intervention. The addition of zolpidem further reduced the score to 8. The patient then underwent ECT thrice in a week, which resulted in a BFCRS score of 0. After 8 ECT sessions, the patient remained symptom-free for 2 weeks. Unfortunately, the patient's symptoms returned 5 days after ECT was discontinued, despite taking Zolpidem at a dose of 40 mg/day and Olanzapine at a dose of 20 mg/day. As a result, maintenance ECT was considered on a weekly basis. The patient did not report any side effects during the course of ECT and was discharged with follow-up plans to continue maintenance of ECT.

For the treatment of catatonia, ECT has been widely recognized as the most effective method. However, intracranial lesions were previously thought to be a relative contraindication for ECT.

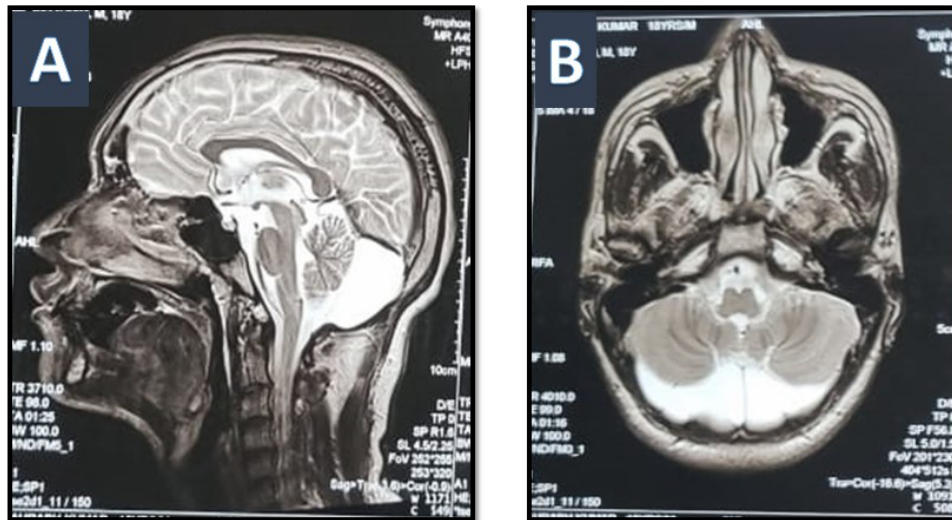


Figure 1. MRI of the brain showing arachnoid cyst behind the cerebellar hemisphere. (A) Sagittal section of the brain and (B) transverse section of the brain.

It was observed that ECT could temporarily increase intracranial pressure, which could potentially worsen the condition of patients with intracranial space-occupying lesions. However, in our case, the patient's intracranial pressure was normal (as evident from the fundoscopic examination), which may have prevented the development of any neurological side effects following ECT treatment. Earlier evidences support the use of ECT to treat catatonia in patients with arachnoid cyst, though the evidence is limited to few published case reports^{2,5} and a retrospective chart review,³ which indicate that ECT is a safe and effective procedure to treat catatonic symptoms and other psychiatric manifestations in patients with arachnoid cysts. One unique feature in our case is reemergence of catatonic symptoms following discontinuation of ECT and resolution of the symptoms with maintenance ECT.

It is difficult to determine if the arachnoid cyst is causing the catatonia and psychotic illness in this case. It is also unclear if the cyst is preventing lorazepam and zolpidem from treating the catatonic symptoms. However, ECT can be considered a safe and effective treatment for catatonia, even with the presence of a benign arachnoid cyst that does not increase intracranial pressure. Careful dosing and frequency of ECT can minimize risks, and personalized treatment with interdisciplinary consultation can improve the chances of recovery. This case highlights the benefits of ECT for psychosis with benign intracranial lesions when phar-

macological therapy is not effective. Some patients may need maintenance ECT to prevent relapse of catatonic symptoms.

Author contribution. Formal analysis: B.K.Y., G.P.; Investigation: B.K.Y., S.K.K.; Project administration: B.K.Y., G.P.; Data curation: G.P., S.K.K.; Writing – original draft: G.P., S.K.K.; Conceptualization: S.K.K.; Supervision: S.K.K.; Writing – review & editing: S.K.K.

Disclosure. None of the authors have any competing interests.

References

1. Margetić B, Palijan TZ, Kovacević D. Homicide and subsequent catatonia associated with a large arachnoid cyst: case report. *Acta Clin Croat.* 2013;52(4):497–505.
2. Wachtel LE, Baranano K, Reti IM. Electroconvulsive therapy for catatonia in a boy with hydrocephalus and an arachnoid cyst. *Pediatr Neurol.* 2010;43(1):73–75. doi:10.1016/j.pediatrneurol.2010.03.011.
3. Lu Y, Tian Y, Gan Y, et al. The efficacy and tolerability of electroconvulsive therapy in psychiatric patients with arachnoid cysts: a retrospective chart study. *Brain Sci.* 2022;12(10):1393. doi:10.3390/brainsci12101393.
4. da Silva JA, Alves A, Talina M, et al. Arachnoid cyst in a patient with psychosis: case report. *Ann Gen Psychiatry.* 2007;6(1):16. doi:10.1186/1744-859X-6-16.
5. Kastenholz KJ, Rosenthal LJ, Dinwiddie SH. Electroconvulsive therapy in a patient with catatonia and an intracranial arachnoid cyst. *J ECT.* 2014;30(4):e53–e54. doi:10.1097/YCT.0000000000000182.