



A narrative review on dietary components and patterns and age-related macular degeneration

Emine Koçyiğit¹, Nazlıcan Erdoğan Gövez^{2*} , Sabriye Arslan² and Duygu Ağagündüz²

¹Department of Nutrition and Dietetics, Ordu University, Ordu, Türkiye

²Department of Nutrition and Dietetics, Faculty of Health Sciences, Gazi University, Ankara, Türkiye

Abstract

Age-related macular degeneration (AMD) is one of the most prevalent eye diseases among the ageing population worldwide. It is a leading cause of blindness in individuals over 55, particularly in industrialised Western countries. The prevalence of AMD increases with age, and genetic factors and environmental influences are believed to contribute to its development. Among the environmental factors, diet plays a significant role in AMD. This review explores the association between dietary components, dietary patterns and AMD. Various nutrients, non-nutrient substances and dietary models that have the potential to counteract oxidative stress and inflammation, which are underlying mechanisms of AMD, are discussed. Consuming fruits, vegetables, fish and seafood, whole grains, olive oil, nuts and low-glycaemic-index foods has been highlighted as beneficial for reducing the risk of AMD. Adhering to the Mediterranean diet, which encompasses these elements, can be recommended as a dietary pattern for AMD. Furthermore, the modulation of the gut microbiota through dietary interventions and probiotics has shown promise in managing AMD.

Key words: age-related macular degeneration: biotics: carotenoids: diet: dietary patterns: Mediterranean diet: nutrition: omega-3: polyphenols: microbiota: zinc

(Received 8 June 2023; revised 25 December 2023; accepted 4 January 2024)

Introduction

Age-related macular degeneration (AMD) is one of the global burdens of eye diseases in the ageing world^(1,2). One of the main factors contributing to blindness is AMD in the industrialised Western countries among those over the age of 55. It is estimated that approximately 9% of all occurrences of blindness are caused by AMD. In a systematic review, the global prevalence of AMD is expected to rise from 196 million in 2020 to 288 million in 2040 worldwide. The progression rate of the disease is rapidly accelerating, resulting in an important public health problem. The incidence of AMD increases with advancing age, and the development of AMD is influenced by both genetic predisposition and environmental factors⁽³⁻⁵⁾. For the dry AMD type, there is currently no pharmaceutical therapy available, while intravitreal anti-vascular endothelial growth factor (anti-VEGF) inhibitors are utilised in the treatment of wet AMD^(6,7). The treatment of AMD includes different approaches including drug therapy, quitting smoking, blood pressure regulation, combination therapy, photodynamic therapy, thermal laser photocoagulation, radiation therapy, surgical intervention and nutritional management⁽⁸⁾.

AMD is a multifaceted disease that can be affected by a wide variety of modifiable and non-modifiable risk factors⁽⁹⁾. Primary modifiable risk factors for age-related macular degeneration include smoking, having a high body mass index, excessive

sunlight exposure, alcohol usage, oxidative changes, a high-fat diet and an inadequate intake of dietary antioxidants. Hypertension, atherosclerosis, a family history of AMD, advanced age, cataract surgery, cardiovascular disease, increased plasma fibrinogen, diabetes and genetics are additional risk factors for AMD. Genome-wide association studies (GWAS) have shown to be by far the most effective method for constructing a genetic risk map related to AMD. Polymorphisms in the complement factor H (*CFH*), age-related maculopathy susceptibility 2 (*ARMS2*) and HtrA serine peptidase 1 (*HTRA1*) genes significantly contribute to the risk of AMD^(10,11).

When it comes to treatment strategies for AMD, there is currently no clinically proven treatment for AMD to be fully effective⁽¹²⁾. This situation increases the importance of strategies to prevent and delay AMD^(12,13). As mentioned above, nutrition and some nutrients, as well as non-nutrient compounds, are among the most important modifiable risk factors for AMD⁽¹⁴⁾. In this context, in a pioneering study in this field on eye diseases known as The Age-Related Eye Disease Study (AREDS), there are some important findings that vitamins such as vitamins C, E and A and zinc reduce the 5-year prognosis of AMD by about 25%⁽¹⁵⁾. These important findings indicated that nutrition has an important role in both the prevention and prognosis of AMD and accelerated research in this area. Again, there is some evidence that some vitamins, phytochemicals and bioactive fatty acids, which are known to have an antioxidant role in reducing the

* Corresponding author: Nazlıcan Erdoğan Gövez, email: nazlicanerdogan@gazi.edu.tr

oxidative stress that increases with age, play a synergistic role in the neutralisation of free radicals/prooxidants⁽¹⁶⁾. In addition to this, with the increasing awareness of nutrition and health among consumers in recent years, studies on both the market availability and health effects of natural products, some phytochemical-based nutraceuticals and important gut modulators such as probiotics and prebiotics, have increased significantly. However, the potential roles of these components in AMD seem to have not been entirely discussed. In the present manuscript, the potential roles and mechanisms of action of nutrients, non-nutrient bioactive compounds and some dietary patterns on AMD, which are closely associated with eye health and AMD, are discussed in detail.

Classifications and clinical alterations of AMD

The retina, situated posteriorly inside the eye, serves as the primary location for the processing of visual information⁽¹⁷⁾. The retina is a divided, multilayered tissue consisting of photoreceptor cells (rods and cones), a network of four types of neurons (bipolar, horizontal, amacrine cells and ganglion), a neurosensory retina consisting of special glial cells, and retinal pigment epithelium (RPE) cells located on Bruch's membrane. RPE cells have a high concentration of melanin. RPE cells have multiple roles in maintaining the health and function of photoreceptor cells and preventing retinal degeneration. These include absorbing light energy and protecting against photooxidation, as well as facilitating the transport of ions, metabolites and fluid across the blood–retinal barrier. Additionally, RPE cells provide essential nutrients such as glucose, retinol and fatty acids to photoreceptor cells^(18,19). The macula, which contains the largest density of cone photoreceptors in the eye and provides central visual acuity, is located in the fovea, the central part of the retina. The macula cells, particularly those in the fovea, play a crucial role in visual acuity. Any deterioration in this region might result in the impairment of central vision or total blindness⁽²⁰⁾. AMD is an example of a retinal disease that impacts the macula. Nutrition plays a crucial role in preserving retinal health, with vitamins, minerals, lutein, zeaxanthin and omega-3 fatty acids playing significant roles in various biochemical processes within the eye and the nutritional composition of the diet impacting on the risk and severity of AMD. Furthermore, nutrition affects the gut microbiota, which through processes such as modulation of low-grade inflammation indirectly impacts on AMD.^(21,22)

Multiple classification methods for AMD exist in the literature and clinical practices. Previous population-based studies have divided AMD into early and late types^(23,24). In clinical applications, the AREDS severity scale and its simplified version were utilised⁽²⁵⁾. Regarding the Beckman classification, AMD is not likely to develop if the drusen are less than 63 µm in diameter. Retinal pigmentary abnormalities in the macula and the occurrence of medium-sized drusen (>63 to ≤125 µm) are considered early AMD, which are often asymptomatic⁽²³⁾. The intermediate stages of the illness, which are usually oligosymptomatic, are characterised by a rise in the size, amount and pigmentation of drusen, which may be seen using fundus imaging of the retina. The late AMD is subdivided into two

subtypes, but both result in severe vision impairment. Late AMD may cause damage to the retina as either a 'wet' type, characterised by unstructured choroidal neovascularisation (CNV), or a 'dry' form, characterised by distinct areas of retinal pigmented epithelium (RPE) cell loss, known as geographic atrophy (GA). The neovascular type of late AMD can advance quickly in weeks or months, whereas the atrophic form progresses more slowly in years or decades^(2,9). The different classifications of AMD are presented in Table 1.

Drusen are one of the first signs of dry AMD. They are small white-yellow deposits between the RPE and the underlying Bruch's membrane. Ubiquitin, integrins, complement, collagen, fibronectins and β-amyloids accumulate in the drusen structure^(29,30). The transition from an initial stage of AMD to GA can be defined as the progression of AMD. The soft drusen are less distinct, and their growth typically involves gradual coalescence. Finally, the soft drusen become a crystalline form, indicative of GA⁽³¹⁾. GA, an advanced form of dry AMD, is characterised by the presence of drusen, deterioration of the choriocapillaris, photoreceptors, RPE and choriocapillaris, atrophic loss of the outer retina, and a slowly progressive loss of visual function^(32–34).

Wet AMD or neovascular AMD is defined by the choriocapillaris-derived formation of new fragile vessels through a breach in the outer aspect of Bruch's membrane, known as CNV, into the sub-pigment epithelial region. Macular oedema/haemorrhaging can occur as these new vessels penetrate the retina. This can lead to a severe RPE detachment and a fast loss of vision, resulting in the formation of a hard exudate and fibrous scar tissue in the macula⁽³⁵⁾. Neovascular AMD is relatively infrequent compared with dry AMD; however, it is responsible for nearly 90% of significant central vision impairment resulting from AMD⁽³⁶⁾. A model of the healthy human eye and the alterations that occur during the early/intermediate and late stages of AMD is given in Fig. 1. Modified risk factors such as a diet that can modulate these alterations are significant to manage this process positively and in a timely manner.

Dietary components and patterns in AMD

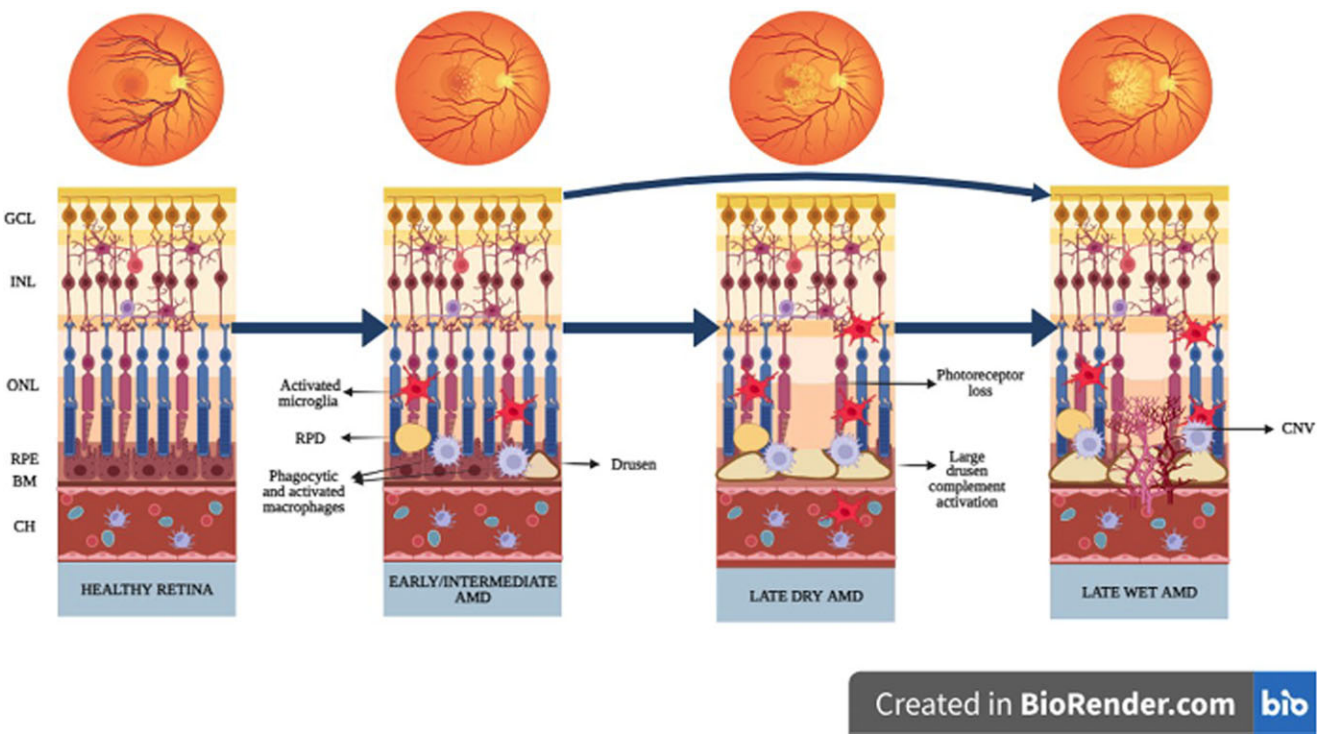
The potential role of micronutrients in AMD is one of the most researched topics. In the literature, the formulations of AREDS and AREDS2 containing certain nutrients have demonstrated positive effects in managing AMD because of their antioxidant composition. The AREDS and AREDS2 formulation contains specific amounts of various vitamins and minerals. The former includes AREDS 500 mg of vitamin C, 400 IU of vitamin E, 15 mg of β-carotene, 80 mg of zinc oxide and 25 mg of copper oxide. The AREDS2, in addition to these components, also contains 10 mg of lutein, 2 mg of zeaxanthin, 350 mg of docosahexaenoic acid and 650 mg of eicosapentaenoic acid^(15,37). Based on the available data, it is recommended that individuals with AMD increase their daily dietary intake with green leafy vegetables and consume oily fish at least twice a week. Furthermore, the Mediterranean diet has a beneficial effect on patients with AMD⁽¹⁴⁾.

Many commercially accessible dietary supplements for people with AMD have been developed, and they often refer

Table 1. Different classifications of AMD

	International Classification and Grading System for AMD ⁽²⁶⁾		Rotterdam Staging System ⁽²⁷⁾	
0a	No signs		No signs of AMD at all	
0b	Few hard drusen (<63 µm)		Hard drusen (<63 µm) only	
1a	Soft distinct (>63 µm)		Soft distinct drusen (≥63 µm) only	
1b	Pigment irregularities only (no soft drusen)		Pigmentary abnormalities only, no soft drusen (≥63 µm)	
2a	Soft indistinct drusen (>125 µm)		Soft indistinct drusen (≥125 µm) or reticular drusen only	
2b	Soft distinct drusen (>63 µm) and pigment irregularities		Soft distinct drusen (≥63 µm) with pigmentary abnormalities	
3	Soft indistinct drusen (>125 µm) and pigment irregularities		Soft indistinct (≥125 µm) or reticular drusen with pigmentary abnormalities	
4			Atrophic or neovascular AMD	
4a	GA		–	
4b	CNV		–	
4c	GA and CNV		–	
	Wisconsin grading ⁽²⁸⁾	Beckman classification ⁽²³⁾	AREDS grading ⁽¹⁵⁾	3-Continent harmonisation ⁽²⁴⁾
No ageing-related changes	–	There is an absence of drusen and pigment abnormalities	–	–
Changes with normal ageing/No AMD	–	Small drusen (≤63 µm) and no abnormalities in the pigment	A few small drusen or none at all	No, questionable, small, or intermediate sized drusen (<125 µm in diameter) only, regardless of area of involvement, and no pigmentary abnormalities (defined as increased retinal pigment or RPE depigmentation present) OR No definite drusen with any pigmentary abnormality
Early AMD	The presence of drusen ≥125 µm or retinal pseudodrusen or pigmentary abnormalities	Medium drusen (>63 to ≤125 µm) without pigment abnormalities	Multiple small drusen or a few drusen of intermediate size (63–124 µm), or RPE abnormalities	
Mild early AMD	–	–	–	Small to intermediate sized drusen (<125 µm in diameter), regardless of area of involvement, with any pigmentary abnormality OR Large drusen (≥125 µm in diameter) with drusen area <331 820 µm ² (equivalent to O-2 circle, defined as a circle with diameter of 650 µm) and no pigmentary abnormalities
Moderate early AMD	–	–	–	Large drusen (≥125 µm in diameter) with drusen area <331 820 µm ² and any pigmentary abnormality OR Large drusen (≥125 µm in diameter) with drusen area ≥331 820 µm ² , with or without increased retinal pigment but no RPE depigmentation
Severe early AMD	–	–	–	Large drusen (≥125 µm in diameter) with drusen area ≥331 820 µm ² and RPE depigmentation present, with or without increased retinal pigment
Intermediate AMD	–	Any anomalies in the pigment or a large drusen >125 µm	A large amount of intermediate drusen or at least one drusen ≥125 µm, or GA not centred on the fovea	–
Late AMD	Neovascular AMD or geographic atrophy	Neovascular AMD or geographic atrophy	–	Pure GA in the absence of exudative macular degeneration OR Exudative macular degeneration with or without GA present
Advanced AMD	–	–	Foveal centre-related GA or any indication of choroidal neovascularisation	–

AMD, age-related macular degeneration; CNV, choroidal neovascularisation; GA, geographic atrophy; RPE, retinal pigmented epithelium.



Created in BioRender.com bio

Fig. 1. Model of the healthy human eye and the alterations that occur during the early/intermediate and late stages of AMD⁽¹⁷⁾. BM, Bruch's membrane; CH, choroid; CNV, choroidal neovascularisation; GCL, ganglion cell layer; INL, inner nuclear layer; ONL, outer nuclear layer; RPD, reticular pseudodrusen; RPE, retinal pigment epithelium.

to AREDS formulations, considering their possible effects. These supplements benefit older individuals with AMD who cannot meet their micronutrient dietary requirements. Once-daily intake can reduce severe vision loss and prevent the development of advanced AMD in people with AMD since the AREDS2 formulation contains 10 mg of lutein + 2 mg of zeaxanthin. It has been reported that using supplements that contain β-carotene is not recommended for individuals who are current or former smokers. In addition, dietary modifications can prevent the onset and progression of AMD^(37,38). A recent systematic review and meta-analysis assessed the effect of nutritional supplements on individuals with AMD. The study found that taking supplements of lutein and zeaxanthin + omega-3 long-chain PUFAs resulted in significant improvements in best corrected visual acuity when compared with the control group (standardised mean difference: 4.59, 95% CI: 1.75, 7.43). Overall, multifocal electroretinogram data showed a considerable improvement following lutein + zeaxanthin intake (standardised mean difference: 4.59, 95% CI: 1.75, 7.43)⁽³⁹⁾. Specific human clinical trials focused on the effect of micronutrients in AMD are presented in Table 2.

Oral dietary supplements are easily accessible, non-invasive and cost-effective, and do not require a medical prescription. On the other hand, dietary supplements were formulated to respond to the nutritional requirements of individuals in optimal conditions to sustain or enhance their wellbeing. They did not serve as treatment for medical issues and were not designed for medical use. Also, a dietary supplement based on the AREDS2 formulation has no known adverse side effects. Compliance with

supplements recommended by AMD professionals is high among patients⁽⁵⁶⁾. Nevertheless, more consensus is required regarding the effects of AREDS-based supplements on AMD prevention. Furthermore, it should be noted that the AREDS2 trial only enrolled people with intermediate AMD, thereby constraining the generalisability of the findings to other types of AMD. Now, ophthalmologists and other healthcare professionals caring for patients with AMD should consider individual differences and potential adverse effects when recommending dietary supplements^(14,57).

Research indicates that individuals with varying risk alleles for AMD may benefit from customised nutritional therapies. However, there needs to be more current information regarding the impact of genetics and various dietary components on the prognosis of AMD. Consequently, obtaining knowledge regarding the optimal nutritional supplements is crucial before carrying out more studies on dietary supplements, such as trials targeting carefully categorised subgroups of patients with AMD while considering genetic data^(39,58).

Vitamin A and carotenoids. The typical visual function requires the presence of vitamin A, and any inadequacy of this vitamin leads to visual dysfunction⁽⁵⁹⁾. In addition, vitamin A is a crucial component in various metabolic processes, including but not limited to promoting the growth of the eye's epithelial tissue, participating in the visual cycle through biochemical transformations, facilitating the re-synthesis of rhodopsin, which is essential for mesopic vision, enhancing epithelial function and preventing conjunctival desiccation^(60,61).

Table 2. Certain human clinical trials focused on the effect of micronutrients in AMD.

Study/author (Ref.)	Population	Study design	Methods/intervention	Results
Seddon <i>et al.</i> (Eye Disease Case-Control Study Group), 1994 ⁽⁴⁰⁾	356 patients with advanced AMD and 520 controls	Case-control	FFQ	Carotenoid intake reduces the risk of AMD (OR 0.57, 95% CI: 0.35, 0.92). Lutein and zeaxanthin intake were most strongly associated with a reduced risk of AMD. Vitamin E and vitamin C consumption and intake of retinol were not associated with a reduced risk of AMD.
AREDS Group, 2001 ⁽¹⁵⁾	3640 participants, 55–80 years old	RCT	I1: antioxidants 500 mg vitamin C + 400 IU vitamin E + 15 mg β-carotene I2: 80 mg Zn + 2 mg Cu oxide I3: antioxidants + Zn and placebo for 6.3 years follow-up	Comparison with placebo demonstrated a statistically significant odds reduction for the development of advanced AMD with antioxidant + zinc (OR 0.72, 99% CI: 0.52, 0.98). The OR for zinc alone was 0.75 (99% CI: 0.55, 1.03). The OR for antioxidants alone was 0.80 (99% CI: 0.59, 1.09). In this high-risk group, both zinc and antioxidants + zinc showed a significant reduction in the risk of advanced AMD development.
Van Leeuwen <i>et al.</i> (The Rotterdam Study), 2005 ⁽⁴¹⁾	5836 participants, ≥55 years of age	Cohort study	FFQ	Dietary intake of both vitamin E and zinc was inversely associated with incident AMD. β-Carotene, vitamin C, vitamin E and zinc were associated with a 35% reduced risk of AMD.
Chong <i>et al.</i> , 2007 ⁽⁴²⁾	149 203 patients	Systematic review and meta-analysis	–	Vitamin A, vitamin C, vitamin E, zinc, lutein, zeaxanthin, α-carotene, β-carotene, β-cryptoxanthin and lycopene have little or no effect in the primary prevention of early AMD.
Parekh <i>et al.</i> (The NHANES III study), 2007 ⁽⁴³⁾	14 464 participants, ≥40 years of age	Cross-sectional study	24-h diet recall and FFQ	Milk intake (400 IU added to a quart or 946 ml of milk) was inversely associated with early AMD (OR 0.75, 95% CI: 0.6, 0.9).
Newsome, 2008 ⁽⁴⁴⁾	40 participants ≥70 years of age	RCT	40 people were given randomly 25 mg zinc or placebo twice daily for 6 months	After 6 months, the zinc group showed improved visual acuity. Zinc at a dose of 25 mg twice daily was found to be well tolerated and resulted in an improvement in macular function in individuals with AMD.
Tan <i>et al.</i> (The Blue Mountains Eye Study), 2008 ⁽⁴⁵⁾	3654 participants, ≥49 years of age	Cohort study	FFQ	Individuals who were in the highest tertile of lutein/zeaxanthin intake had a decreased risk of incident neovascular AMD (RR 0.35, 95% CI: 0.13, 0.92). Individuals with higher than median intakes of lutein/zeaxanthin exhibited a lower risk of developing indistinct soft or reticular drusen (RR 0.66, 95% CI: 0.48, 0.92). The incidence of neovascular AMD was predicted by the lowest tertile of total β-carotene intake (RR 2.68, 95% CI: 1.03, 6.96). RR of developing any AMD and early AMD was significantly lower in individuals with the highest decile of zinc intake compared to the rest of the population. The RR for any AMD was 0.56 (95% CI: 0.32, 0.97) and for early AMD was 0.54 (95% CI: 0.30, 0.97). Higher intake of vitamin E was associated with an increased risk of developing late AMD. The RR for the middle and highest tertiles were 2.55 (95% CI: 1.14, 5.70) and 2.83 (95% CI: 1.28, 6.23), respectively, when compared with the lowest tertile.
Christen <i>et al.</i> , 2009 ⁽⁴⁶⁾	5442 female participants ≥40 years of age	RCT	I: 2.5 mg folic acid 50 mg vitamin B ₆ 1 mg vitamin B ₁₂ and placebo for 7.3 years of follow-up	Daily supplementation with folic acid, B ₆ and B ₁₂ for an average duration of 7.3 years may reduce the risk of AMD by 35–40%.
Weigert <i>et al.</i> (AREDS study), 2011 ⁽⁴⁷⁾	116 participants ≥70 years of age	RCT	The dosage in months 1–3 was 20 mg lutein once daily and in months 4–6 was 10 mg lutein once daily	Lutein significantly increased macular pigment optical density by 27.9 ± 2.9%. A significant correlation was found between the increase in macular pigment optical density, mean differential light threshold and visual acuity.

Table 2. (Continued)

Study/author (Ref.)	Population	Study design	Methods/intervention	Results
Snellen <i>et al.</i> , 2012 ⁽⁴⁸⁾	72 patients with neovascular AMD and 66 controls ≥60 years of age	Case-control	Antioxidant FFQ	The prevalence rate of AMD in patients with low antioxidant intake and low lutein intake was approximately twice as high as that in patients with high intake (OR 1.7, 95% CI: 0.8, 3.7 and OR 2.4, 95% CI: 1.1, 5.1, respectively).
AREDS Group, 2013 ⁽³⁷⁾	4203 participants, 50–85 years old	RCT	I1: 10 mg lutein + 2 mg zeaxanthin I2: 1.0 g omega-3 long-chain polyunsaturated fatty 3 acids I3: 10 mg lutein + 2 mg zeaxanthin + 1.0 g omega-3 long-chain polyunsaturated fatty 3 acids and placebo in addition to AREDS formulation for 4.9 years of follow-up	Lutein + zeaxanthin versus no lutein + zeaxanthin, the HR of the development of late AMD was 0.90 (95% CI: 0.82, 0.99). The addition of lutein + zeaxanthin, as well as DHA + EPA, or a combination of both, into the AREDS formulation did not result in a decrease in the risk of progressing to an advanced AMD. The substitution of carotenoids with lutein and zeaxanthin is a possible option, given the potential rise in lung cancer prevalence among previous smokers.
Gopinath <i>et al.</i> (The Blue Mountains Eye Study), 2013 ⁽⁴⁹⁾	1390 patients ≥65 years of age	Cohort study	FFQ	Supplementary vitamin B ₁₂ intake had 47% reduced risk of incident of any AMD (OR 0.53, 95% CI: 0.33, 0.85).
Hammond <i>et al.</i> , 2014 ⁽⁵⁰⁾	115 young healthy participants <30 years of age	RCT	57 people were given lutein + zeaxanthin supplements (10 mg/2 mg), and 58 people were given placebo	The group that received lutein + zeaxanthin exhibited a significant increase in macular pigment optical density compared with the placebo group. A significant association was observed between the longitudinal changes in MPOD and visual function.
Smailhodzic <i>et al.</i> , 2014 ⁽⁵¹⁾	72 patients with AMD ≥70 years of age	Open-label clinical study	50 mg zinc sulphate + 1 mg cupric sulphate daily for 3 months	The daily administration of 50 mg of zinc sulphate has been found to have inhibitory effects on complement catabolism in patients with AMD who exhibit increased complement activation.
Aoki <i>et al.</i> , 2016 ⁽⁵²⁾	157 patients with AMD and 369 controls	Case-control	A brief-type self-administered questionnaire on diet history	Low intakes of α-tocopherol, zinc, vitamin D, vitamin C and β-carotene were associated with neovascular AMD. There was no association with retinol or cryptoxanthin intake and neovascular AMD.
Braakhuis <i>et al.</i> , 2017 ⁽⁵³⁾	42 patients with oxidative stress-related AMD and 149 controls ≥60 years of age	Case-control	Antioxidant FFQ	Beneficial relationship was observed between the increased intake of vitamin C (OR 0.63, 95% CI: 0.23, 1.03) and β-carotene (OR 0.56, 95% CI: 0.15, 0.98) with oxidative stress-related AMD.
Merle <i>et al.</i> , 2017 ⁽⁵⁴⁾	2146 participants	Prospective study	FFQ	A lower risk of progression to advanced AMD in the highest versus lowest quintile of dietary vitamin D intake was determined (HR 0.60, 95% CI: 0.43, 0.83).
Parravano <i>et al.</i> , 2019 ⁽⁵⁵⁾	30 patients with intermediate AMD	Double-masked RCT	I: 20 mg lutein + 4 mg zeaxanthin + 140 mg N-acetylcysteine + 80 mg bromelain 2500 GDU + 800 IU vitamin D ₃ + 18 mg vitamin B ₁₂ + 140 mg α-lipoic acid + 157 mg rutin + 160 mg vitamin C + 16 mg zinc oxide + 36% <i>Vaccinium myrtillus</i> + 90 mg anthocyanosides + 600 mg <i>Ganoderma lucidum</i> two tablets per day and placebo (P)	After a period of 6 months of follow-up, eyes affected in patients with intermediate AMD exhibited a significant improvement in the intensity of multifocal electroretinogram response amplitude density that was detected from the macular regions located at the centre. There were no statistically significant changes observed in the retinal and choroidal spectral domain-optical coherence tomography parameters when compared with the baseline values.

AMD, age-related macular degeneration; CI, confidence interval; FFQ, food frequency questionnaire; HR, hazard ratio; I, intervention group; MPOD, macular pigment optical density; NHANES, National Health and Nutrition Examination Survey; OR, odds ratio; P, placebo group; RCT, randomised controlled trial; RR, relative risk.

The most common vitamin A compounds in foods derived from animals, including dairy products, eggs, fish, meat and liver, are retinol and retinyl esters. Provitamin A carotenoids, including β -carotene, α -carotene and β -cryptoxanthin, present in plant-based foods, convert to vitamin A within the organism. Sources of provitamin A go through metabolic processes that produce vitamin A, which is utilised by the organism according to its physiological needs. The rest of the carotenoids retain their antioxidant properties, such as lutein, zeaxanthin and lycopene^(62,63). Carotenoids are potent antioxidants that can reduce the systemic oxidative stress that influences the macula. α -Carotene, β -carotene and lycopene have been observed in the human RPE and choroid. These compounds protect these tissues against oxidative damage caused by exposure to light and the generation of free radicals within the local environment⁽²¹⁾.

Vitamin A has been associated with various retinal diseases, directly or indirectly. Some diseases are linked to pathogenic variations in genes that encode proteins that play a direct role in the vitamin A pathways in the retina. This can result in a deficiency of vitamin A in the affected area and/or the formation of bis retinoids. In the membranes of the outer photoreceptor segments, toxic bis retinoids are transformed into the bis retinoid pyridinium compound A2E and related bis retinoids. Due to the postmitotic character of RPE cells and the inability of A2E to go through further metabolism, the accumulation of A2E and its related bis retinoids occurs in the form of lipofuscin deposits within the RPE. Lipofuscin accumulation, which plays a role in the pathogenesis of AMD, impairs the functionality and longevity of RPE cells, leading to the degeneration of photoreceptors and consequent visual impairment. Others include local deficit brought on by the indirect transfer of vitamin A from the choroid to the retina or visual impairment induced by malfunction of the visual pigments. Since AMD results in the formation of bis retinoids, vitamin A supplementation should be controlled in those with AMD^(60,61,63).

Lutein, zeaxanthin and meso-zeaxanthin are macular xanthophylls synthesised from lutein within the retina⁽⁶⁴⁾. High levels of macular xanthophylls are found in the macular lutea of the eye. The centre of the fovea is known to possess the highest concentration of lutein and zeaxanthin; the lens also contains both^(65,66). When lutein and zeaxanthin interact with free radicals, lycopene takes in their unpaired electrons⁽⁶¹⁾. Lutein and zeaxanthin levels are high in eggs and a variety of fruits and vegetables, especially green leafy vegetables, including kale, spinach, broccoli and parsley^(5,67).

Lutein and zeaxanthin can selectively absorb blue light and decrease oxidative stress in the retina, impeding the formation of reactive oxygen species, particularly singlet oxygen, within the retinal tissue. The mechanisms of lutein and zeaxanthin include their antioxidant, antiangiogenic and anti-inflammatory capabilities, as well as their ability to prevent phototoxic damage by absorbing solar radiation, to lessen oxidative stress by scavenging ROS and to reduce inflammation^(68,69). Moreover, the pi-class glutathione *S*-transferase isoform, known as GSTP1, along with the zeaxanthin- and mesozeaxanthin-binding protein in the retina, are significant in protecting the retina against damage from oxidation and regulating the antioxidant levels in the macula⁽⁷⁰⁾. Similarly, the human retinal lutein binding protein

significantly improves the localisation of lutein to the area under oxidative stress⁽⁷¹⁾.

According to a prospective cohort study based on population, a longer intake of fruits and vegetables containing provitamin A carotenoid has decreased the risk of developing AMD⁽⁷²⁾. However, epidemiological research indicates that dietary vitamin A intake does not lower the risk of AMD^(40,73). Supplementation with carotenoids has the potential to reduce the risk of developing AMD and other ocular diseases. The effect of dietary supplements containing β -carotene on the development and onset of AMD was assessed in a significant clinical study known as the AREDS. However, research indicates that high dosages of β -carotene (30 mg/d) may be detrimental to smokers and may increase the risk of lung cancer, making the use of β -carotene supplements inconsistent⁽¹⁵⁾. It is recommended to avoid taking β -carotene supplements to individuals diagnosed with AMD who smoke. As a result, the revised AREDS2 formula has substituted β -carotene with lutein and zeaxanthin. Research has demonstrated that regular use of AREDS2 is associated with a lower risk of developing advanced AMD⁽³⁷⁾.

In recent years, it has been suggested that lutein and zeaxanthin not only inhibit the formation of AMD but also its progression^(18,74). In the Blue Mountains Eye Study, people who consume higher amounts of lutein and zeaxanthin exhibit a lower risk of developing drusen or AMD. However, a significant positive correlation between dietary β -carotene intake and AMD was discovered⁽⁴⁵⁾. Furthermore, a number of research studies have demonstrated that the intake of lutein may enhance the optical density of macular pigment^(47,75). The decline in the concentrations of lutein, zeaxanthin and mesozeaxanthin within the ageing retina is a contributing factor to the important progress of AMD. Support for therapy with these carotenoids may be effective in addition to clinical treatment. The ageing retina has a substantial decline in its natural antioxidant capacity as lutein, zeaxanthin and meso-zeaxanthin levels decrease. This factor plays a crucial role in the advancement of the disease.

The use of carotenoid vitamin treatment as an additional nutraceutical approach in persons diagnosed with AMD has demonstrated positive clinical outcomes in terms of visual function.

Vitamin D. Two major forms of vitamin D are present, namely vitamin D₂ (ergocalciferol) derived from plants and vitamin D₃ (cholecalciferol) obtained from animal-based food sources (animal fats, eggs and fish oil). In humans, vitamin D₃ is produced by the photolysis of 7-dehydrocholesterol when skin is exposed to sunlight (UV-B radiation). Vitamin D₃ is synthesised by the skin and then undergoes two essential hydroxylation processes in the liver (25 (OH) hydroxylation) and kidneys (1,25 (OH)₂ hydroxylation)^(76,77).

The expression of the vitamin D receptor and enzymes associated with vitamin D metabolism (CYP27B1 and CYP24A1) in the retina, RPE and choroid indicates a possible physiological function for vitamin D in AMD. Vitamin D has been found to protect against free radicals in the retina. Additionally, it has been observed to inhibit inflammation by preventing the accumulation of amyloid β plaques and suppressing pro-inflammatory



cytokines that are secreted by macrophages and microglia. Furthermore, it has been found to inhibit angiogenesis through the inhibition of hypoxia-inducible factor (HIF-1) transcription, induction of endothelial cell apoptosis and metalloproteinase MMP-9^(21,77,78).

The association between vitamin D and AMD is a still developing field of study. The findings of a meta-analysis indicate a statistically significant association between late AMD and low circulating levels of 25-hydroxyvitamin D (25(OH)D) below 50 nmol/l (20 ng/ml)⁽⁷⁹⁾. Observational studies^(80,81) and a case-control study⁽⁸²⁾ have demonstrated a negative correlation between plasma vitamin D levels and either early or late atrophic or neovascular AMD. Further research is required due to the heterogeneity in current studies and the lack of prospective studies.

The literature lacks sufficient research to assess how vitamin D supplementation affects AMD incidence and progression. In the United States, a study showed that there is a negative correlation between the early onset of AMD and the intake of milk enriched with vitamin D, which contains an additional 400 IU added to a quart or 946 ml of milk⁽⁴³⁾. The study found that there was a decrease in the severity of AMD and a reduction in the size of drusen in individuals with higher dietary vitamin D intake (a food frequency questionnaire was used to collect data) as compared with their identical twins who had lower dietary vitamin D intake⁽⁸³⁾. Merle *et al.*⁽⁵⁴⁾ showed that a diet rich in Vitamin D may prevent or delay progression to advanced AMD, especially neovascular AMD. The increase in dietary vitamin D intake has been shown to have a protective impact against AMD in the meta-analysis⁽⁷⁹⁾ and recent prospective research⁽⁸⁴⁾. Vitamin D possesses antioxidant and anti-inflammatory capabilities inside the macula, which may have a protective impact on RPE and choroid cells by mitigating oxidative stress, inflammation and apoptosis. Future clinical studies examining the association between vitamin D and AMD will be prompted by possible effects of vitamin D.

Vitamin E. Vitamin E is a fat-soluble antioxidant, found in the cellular membrane of photoreceptors and the RPE, and an effective scavenger of free radicals. Age-related changes in the eyes are increased in cases of vitamin E deficiency. A deficiency of vitamin E may result in an accumulation of lipofuscin, impairment of the retina, and depletion of photoreceptor cells^(85,86). Eight distinct chemical forms of vitamin E occur naturally, with α -tocopherol being the most biologically active among them⁽⁸⁷⁾. Dietary products rich in vitamin E include almonds, walnuts, olive oil, rapeseed oil, hazelnuts, fish, oysters, eggs and butter⁽⁸⁸⁾.

The Rotterdam Study, a population-based cohort that includes individuals aged 55 and above, has revealed an inverse correlation between dietary vitamin E intake and AMD after an 8-year follow-up period⁽⁴¹⁾, whereas the Eye Disease Case-control Study Group did not observe a statistically significant interaction between the risk of AMD and vitamin E⁽⁴⁰⁾. Furthermore, in the population cohort Blue Mountains Eye Study, the participants were divided into three groups based on their vitamin E intake, and a significant correlation was found between vitamin E intake and late AMD incidence in individuals who consumed moderate and high amounts of vitamin E⁽⁴⁵⁾.

A high vitamin E supplementation dose may not always be beneficial for eye health according to the previous studies. The recommended tolerated upper intake level for synthetic vitamin E is 1100 IU. Higher dosages may result in bleeding diathesis, particularly in those using anticoagulants and antiaggregants. Furthermore, a research study revealed that increased intake of vitamin E was associated with a higher risk of developing prostate cancer^(89,90). Clinical studies have demonstrated potential benefits of vitamin E for individuals diagnosed with AMD. Literature suggests that the use of vitamin E supplements, in addition to a regular diet, may have adverse effects and should be administered by medical professionals.

Vitamin C. Vitamin C (ascorbic acid) is a potent antioxidant that is soluble in water and non-enzymatic in nature. Its primary function is to protect proteins, lipids, carbohydrates and nucleic acids from the detrimental effects of free radicals and reactive oxygen species. Many fruits (i.e. oranges, lemons, mangoes, strawberries and blueberries) and vegetables (i.e. broccoli, peppers, potatoes, cauliflower, leafy greens and tomatoes) are considered to be great sources of vitamin C⁽⁹¹⁾.

Through its powerful antioxidant effects, vitamin C benefits eye health and reduces the risk of AMD. Although vitamin C has been shown to have beneficial effects on eye health, the findings from various studies investigating the association between dietary vitamin C intake and the risk of AMD are uncertain^(92,93). In a systematic review and meta-analysis conducted by Chong *et al.*, antioxidant compounds, such as vitamin C, did not significantly contribute to the primary prevention of early AMD⁽⁴²⁾. A case-control study showed that dietary intake of vitamin C was associated with a reduced risk of neovascular AMD⁽⁵²⁾. A Cochrane analysis reported that there was no evidence that vitamin C alone prevents the development of AMD⁽⁹⁴⁾. The outcome was consistent with the research findings described in the manuscript by Delcourt *et al.* There was no statistically significant association between the intake of vitamin C and the incidence of AMD⁽⁷²⁾. Considering the positive effects of vitamin C and the findings of the research, further studies employing larger cohorts are necessary to assess the adequacy of vitamin C in reducing the risk of AMD.

B vitamins. The B vitamins, especially B₆, folate and B₁₂, play a regulatory role in homocysteine levels⁽⁹⁵⁾. Homocysteine is a powerful oxidiser that has the potential to aggravate injury caused by oxidative stress. Elevated levels of homocysteine in the serum have been found to have a direct impact on the damage of epithelial tissue and the disruption of the junction of RPE, potentially resulting in the development of neovascularisation. Increased levels of homocysteine have the potential to stimulate inflammatory processes that can lead to the development of atherosclerosis. High levels of homocysteine have been identified as a possible risk factor for AMD^(96,97).

Studies in the field of epidemiology have established a correlation between increased consumption of vitamin B₆ and folate and a decreased risk of developing AMD⁽⁹⁸⁻¹⁰⁰⁾. In a 10-year population-based cohort study, an inverse correlation was found between the total intake of vitamin B₁₂ and folate equivalents and the incidence of AMD over a period of

10 years. These correlations were not affected by potential confounders including smoking, leucocyte count, fish consumption, renal function or antioxidant intake⁽⁴⁹⁾. A randomised, double-blind, placebo-controlled study with females showed that women with high cardiovascular disease risk who used a combination of folic acid (2.5 mg/d), vitamin B₆ (50 mg/d) and vitamin B₁₂ (1 mg/d) for an average duration of 7.3 years had a decrease in AMD risk by 35–40%⁽⁴⁶⁾.

AMD risk is increased by low plasma folate and B₁₂ concentrations^(49,101). The Alienor Study assessed the association between the diet and plasma levels of B vitamins, including folate, vitamin B₆ and vitamin B₁₂. The study findings indicated that maintaining normal serum folate levels (≥ 10 nmol/l) may lead to a 51% reduction in the risk of developing AMD. Additionally, a 28% decrease in risk was observed in individuals who consumed higher dietary vitamins B₅ and B₆⁽¹⁰²⁾. Research indicates that B vitamins play a beneficial role in preventing the onset and advancement of macular degeneration. Reducing AMD-related vision loss may be possible by using a balanced diet high in B vitamins.

Zinc. It has been determined that approximately 30% of older adults in industrialised countries have a zinc deficiency, and that zinc may play a significant role in AMD and other ageing-related degenerative diseases⁽¹⁰³⁾. Zinc-rich foods include pork, chicken and beef. Zinc is present in legumes, cereals and nuts; however, plant-based phytates can inhibit zinc absorption⁽¹⁰⁴⁾. Zinc is involved in the process of rhodopsin regeneration and the phototransduction cascade in photoreceptor cells. It is an antioxidant ion that serves as a cofactor for several ocular enzymes that are involved in the oxidative process, including superoxide dismutase and catalase^(105,106). Zinc also helps suppress the chronic inflammation in the retina that contributes to AMD by binding complement factor H and inducing the loss of complement 3b's inhibitory activity⁽¹⁰⁷⁾.

In AMD, the level of zinc in the human RPE/choroid is reduced by 24%⁽¹⁰⁵⁾. Smailhodzic *et al.* found that the daily intake of 50 mg of zinc sulphate had an inhibitory effect on complement catabolism in patients with age-related AMD who exhibited increased complement activation⁽⁵¹⁾. The systematic review determined that the current evidence regarding the effectiveness of zinc intake in preventing AMD was not conclusive⁽¹⁰⁸⁾. AREDS study showed that the use of a zinc supplement (80 mg) alone resulted in a decrease in the risk of developing advanced AMD in individuals with intermediate AMD and those with advanced AMD in one eye. The risk of losing visual acuity in AREDS patients was not decreased by zinc treatment alone. The formulation of AREDS included a copper supplementation of 2 mg/d, as it has been observed that elevated levels of zinc can inhibit the absorption of copper⁽¹⁵⁾. The AREDS2 clinical trial investigated the impact of a reduced dosage of zinc (25 mg versus 80 mg) on the progression of AMD, but no statistically significant difference was observed⁽¹⁰⁹⁾. The Blue Mountains Eye Study suggested a threshold dose of 15.8 mg to prevent any adverse effects⁽⁴⁵⁾. Zinc has shown potential for preventing the progression of advanced AMD. Nevertheless, it should be noted that the use of zinc alone may not yield substantial clinical improvements in

visual acuity. When combined with antioxidants, zinc can enhance visual acuity in patients with AMD.

Copper and selenium. Copper plays a significant role in the scavenging and reduction of free radicals due to its unique capacity to quickly acquire and distribute electrons⁽¹¹⁰⁾. Due to the possibility that high zinc dosages might result in copper deficiency anaemia, 2 mg of copper oxide was included in the formulation of AREDS⁽¹⁵⁾.

Selenium has been identified as a constituent element in various enzymes within the organism and has been observed to exhibit antioxidant characteristics. Glutathione peroxidase that is selenium dependent is crucial in preventing oxidative damage to membrane lipids. It was hypothesised that the macula may be protected from oxidative damage by glutathione peroxidase because it had a lowering effect on hydrogen peroxide and other potential hydroperoxides in the cell^(111–113). Furthermore, it was determined that a low intake of selenium in the laboratory animals resulted in a reduction of overall polyunsaturated fatty acids in both the RPE and the outer segments of the retinal rods⁽¹¹⁴⁾.

Over recent years, many studies have been conducted to investigate the impact of selenium on AMD^(111,112). Nevertheless, the outcomes of these investigations have not yielded conclusive evidence. Consumption of an excessive amount of selenium has been found to be detrimental to the human body, leading to adverse effects on endocrine and neurological functioning, as well as causing hepatotoxicity and gastrointestinal problems. Furthermore, it is widely recognised that there exists an antagonistic interaction among zinc and copper. Elevated consumption of zinc in the diet has been seen to result in a decrease in the concentration of copper. Further investigation is required to investigate the relationship between selenium and copper with AMD and ocular diseases.

Genetics and dietary supplements

The importance of genetic testing prior to supplement selection and the potential effects of supplements on AMD within distinct genotype groups are topics of continuing research discussion. The two genes most closely linked to AMD and its development are *CFH* and *ARMS2*. Subjects who have homozygous *CFH* and *ARMS2* risk alleles exhibit an increased tendency for disease progression compared with those who have homozygous non-risk alleles^(115,116). A recent large GWAS has identified the first genetic association specific to wet AMD near the matrix metalloproteinase 9 (*MMP9*) gene. Rare coding variations in TIMP metalloproteinase inhibitor 3 (*TIMP3*), complement factor I (*CFI*) and *CFH* as well as a splice variant in solute carrier family 16 member 8 (*SLC16A8*) have been suggested as having causal involvement for these genes⁽¹¹⁷⁾.

The use of zinc supplementation did not result in any beneficial outcomes for individuals with one or two *CFH* risk alleles during a 10.2-year duration, as evidenced by a study. However, the same individuals were able to derive the maximum benefit from antioxidant therapy (in the AREDS formulation). Individuals with the *ARMS2* risk allele reported that antioxidant treatment alone increased disease progression⁽⁵⁸⁾.

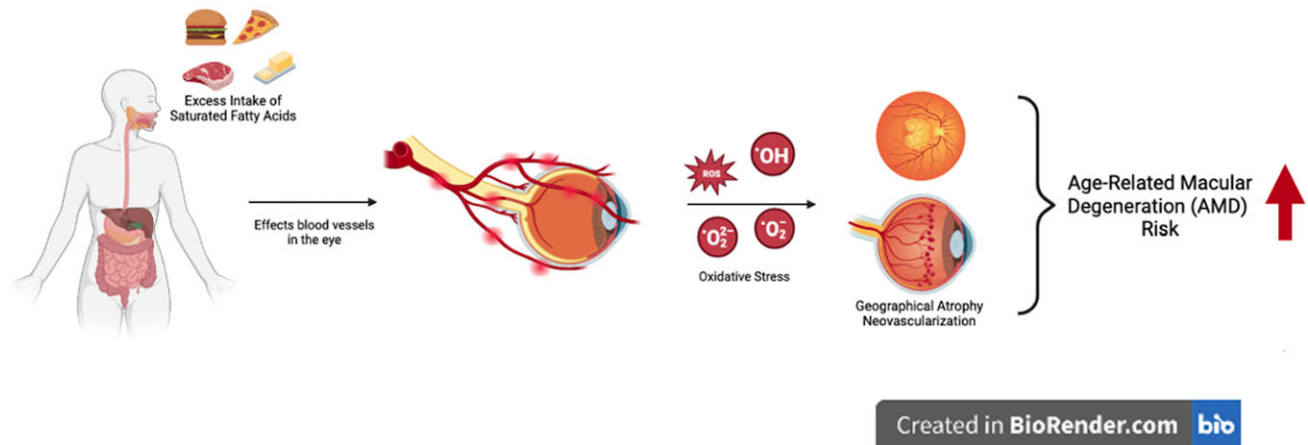


Fig. 2. Potential relationship between the excess intake of saturated fatty acids and AMD risk.

The authors acknowledged the observation that the efficacy of antioxidants diminished in the presence of two *ARMS2* risk alleles, an outcome that can be attributed to their impact on mitochondrial localisation and consequent oxidative phosphorylation^(118,119). The research findings indicate that the mean 10-year progression rates for patients administered with placebo, AREDS formulation and genotype-directed therapy were 47%, 40.5% and 31.7%, respectively, based on the distribution of genetic risk alleles. These results suggest the potential effectiveness of genotype-directed nutritional therapy⁽⁵⁸⁾. Based on the findings of the Rotterdam Study, an intake of dietary antioxidants could decrease the risk of early AMD in individuals with a high genetic risk for *CFH* and *ARMS2*⁽¹²⁰⁾. In addition, genetic differences may account for 27% of variation in response to lutein and zeaxanthin supplementation during a 6-month period among women participants in the AREDS study, as well as 67% of variation in macular pigment optical density^(121,122).

The growing importance of genetic research and the identification of risk alleles in individuals diagnosed with AMD may facilitate the progression of nutrigenomic research. Thus, the encouragement of the selection of dietary modifications that exhibit positive effects on AMD in particular genotype groups may be enabled. However, future investigations are needed to decide on the role and possibility of the usage of dietary supplements and effectiveness regarding personalised medicine in AMD.

Dietary fats

Dietary fats can be classified mainly as saturated fatty acids (SFA) and unsaturated fatty acids (monounsaturated (MUFA) and polyunsaturated (PUFA))⁽¹²³⁾. Several studies have been conducted to clarify the impact of different dietary habits on AMD development. Therefore, several attempts have been performed to define the connection between dietary fat intake and the risk of AMD^(124–129).

Saturated fatty acids. Although the results of the studies vary, several researchers have evaluated the link between the

consumption of SFA and AMD^(124–130). Some scientific evidence points to a link between dietary fat intake – particularly SFA and cholesterol – and an elevated risk of atherosclerosis. Therefore, consuming excess SFA can encourage atherosclerosis and increase the risk of AMD. The proposed mechanism is that the presence of common risk factors between cardiovascular disease and AMD, such as dietary fat, which is linked to atherosclerosis, may have an impact on the blood vessels in the eyes or may participate in oxidative processes that contribute to the progression of AMD in advanced stages, which are characterised by choroidal atrophy or neovascularisation⁽¹³¹⁾ (Fig. 2). Mares-Perlman *et al.* found an elevated risk of early AMD in individuals with the highest intake of cholesterol and SFA⁽¹³⁰⁾.

Similarly, Seddon *et al.* described a trend for an increase in risk for higher intake of SFA for the highest intake compared with the lowest intake (odds ratio (OR) 2.03, $p = 0.07$)⁽¹³²⁾. Delcourt *et al.* revealed an association between SFA intake and increased risk for AMD (OR 2.70, $p = 0.04$)⁽¹²⁸⁾, and according to a study by Cho *et al.*, people who consume a high amount of SFA in their diet have a slightly increased chance of developing AMD⁽¹²⁶⁾. In another study, higher SFA intake was associated with a higher prevalence of overall intermediate AMD in females <75 years ($p = 0.01$)⁽¹²⁹⁾, and Smith *et al.* reported a borderline significant association between SFA intake and the risk for early AMD⁽¹²⁵⁾. In contrast to the previous studies, Sasaki *et al.* found that participants in the highest quartile of SFA intake were less likely to have early AMD compared with the lowest quartile (OR 0.71, 95% CI: 0.52–0.96), and a significant trend for decreased risk of early AMD with increased SFA intake was determined ($p = 0.011$)⁽¹³³⁾. Similarly, Yasukawa *et al.* revealed that SFA intake was inversely associated with the prevalence of AMD in males (OR 0.86), and significant trends were found for decreasing AMD with increased SFA ($p = 0.02$)⁽¹³⁴⁾. In a meta-analysis by Zhong *et al.*, a 10 g/d increment in SFA was not correlated with the risk of any AMD, and there was no proof of a non-linear association between dietary SFA and early and advanced AMD risk ($p = 0.675$ and $p = 0.814$, respectively)⁽¹³⁵⁾. Likewise, Tan *et al.* and Seddon *et al.* found no significant association between the intake of SFA and AMD^(124,136). Diets that are high in saturated fat encourage the flowering of bacteria

that produce endotoxins and break down sulphates, including *Bilophila wadsworthia* (Proteobacteria phylum), which is linked to the degeneration of mucus layers and low-grade inflammation⁽¹³⁷⁾. Since inflammation is the basis of AMD, its association with saturated fat may be relevant. In addition, cholesterol is the primary sterol in the retina. It is extensively present in the drusen, a defining feature of early AMD, and the risk of AMD is increased by a diet high in cholesterol and saturated fat^(138,139). ApoB can produce lipoprotein-like particles that build up in Bruch's membrane with ageing. RPE and photoreceptor outer segments are used to assemble lipoprotein lipids. Additionally, there was evidence that the microbiota affected systemic lipids, and systemic lipid dysregulation was a component of AMD. Large cholesteryl ester-rich lipoproteins built up in healthy people's macular Bruch membrane^(140,141). In addition, the TT genotype of the hepatic lipase gene, *LIPC*, was linked to a 50% reduction in risk for AMD, compared with individuals with the CC variation, in genes implicated in cholesterol transport⁽¹⁴²⁾. The intricacy of this relationship between SFA and AMD is further compounded by other factors, including the impact of microbiota on lipid metabolism, genetic polymorphisms associated with cholesterol transport, and lipid dysregulation in AMD. Although some studies suggest a potential link between SFA and the risk of AMD, the varied results and the complex nature of AMD's multifaceted aetiology necessitate further research to gain a more comprehensive understanding of the intricate interplay among dietary fats, lipid metabolism, genetic factors and the onset of AMD.

Monounsaturated fatty acids. Parekh *et al.*⁽¹²⁹⁾ demonstrated the role of MUFAs as a preventative factor for intermediate AMD. In a study by Delcourt *et al.*, after adjustments for age and gender, the risk of AMD was increased in subjects with a high intake of MUFA (OR 3.50, $p = 0.03$)⁽¹²⁸⁾. The Blue Mountains Eye Study reported an OR of 1.48 for MUFA for early AMD⁽¹²⁵⁾, and MUFA increased the likelihood of progression of AMD in another study (Relative risk (RR) 2.21, $p = 0.04$)⁽¹³²⁾. Additionally, a higher risk of AMD development was linked to a diet high in MUFA⁽¹⁴³⁾, and Seddon *et al.* found a significant relationship between MUFA and advanced AMD (OR 1.71, $p = 0.03$). It was thought that this might be because MUFA sources are also a source of SFA, and after additional adjustments for protein and SFA, PUFA and trans saturated fats, it was determined that the relationship was no longer statistically significant⁽¹³⁶⁾. The AREDS team suggested a possible justification for these disparate outcomes: People who consumed the most MUFAs had a higher risk of developing neovascular AMD. However, this link disappeared when docosahexaenoic acid (DHA), arachidonic acid and other nutrients (lutein/zeaxanthin) were considered⁽¹²⁷⁾. In a meta-analysis, consumption of MUFA was not significantly associated with early or advanced AMD⁽¹³⁵⁾. Similarly, Sasaki *et al.* did not find any significant relationship in their study⁽¹³³⁾. Oleic acid is one of the MUFAs that may protect against AMD. However, only a few studies have looked at this relationship. In studies, olive oil, one of the primary dietary sources of oleic acid, has been strongly linked to a lower risk of AMD^(144,145).

Furthermore, in addition to oleic acid, olive oil also includes other substances, such as polyphenols, that may play a protective function in AMD. It is, therefore, challenging to

determine if these health advantages are due to oleic acid or other olive oil substances⁽¹⁴⁶⁾. A study determined that after adjustment for potential confounders, regular use of olive oil was significantly associated with a decreased risk of late AMD (OR 0.44). However, there were no statistically significant correlations between regular olive oil consumption and the *CFH* rs1061170, *ARMS2* rs10490924, *LPL* rs12678919 or *LIPC* rs493258 polymorphisms, which are genetic risk factors for AMD⁽¹⁴⁷⁾. The bioactive components of olive oil may be responsible for the preventive mechanisms behind the link between the consumption of olive oil and lower odds of late AMD. The unsaponifiable fraction of olive oil consists of phenolic substances with antioxidant and anti-inflammatory characteristics, such as oleuropein, hydroxytyrosol, tyrosol and oleocanthal⁽¹⁴⁸⁾. Oleocanthal, a substance that resembles the non-steroidal anti-inflammatory medicine ibuprofen, appears to be the primary mediator of the anti-inflammatory effects⁽¹⁴⁹⁾. Additionally, hydroxytyrosol and oleuropein, which have antioxidant properties, inhibit the oxidation of LDL-cholesterol and decrease the expression of genes and proteins that control inflammation^(150,151). In addition, hydroxytyrosol protects against mitochondrial malfunction and oxidative damage in retinal pigment epithelial cells *in vitro*⁽¹⁵²⁾.

The interaction of MUFAs, constituents of olive oil, and the AMD encompasses several processes, encompassing the effects of reducing inflammation and oxidative stress. However, in addition to the aforementioned points, it is evident that the consumption of monounsaturated fatty acids (MUFAs), particularly olive oil, and therefore the adherence to the Mediterranean diet, provide a multitude of advantageous effects on human health. In this particular situation, it is recommended to keep to the consumption of MUFAs in accordance with the prevailing dietary recommendations.

Polyunsaturated fatty acids. In the body, PUFAs (linoleic acid (LA) and α -linolenic acid (ALA)) are converted to very-long-chain PUFAs by fatty acyl-CoA synthetases, and their respective elongases designated as elongation of very long fatty acids. Eicosapentaenoic acid (EPA) and docosahexaenoic acid (DHA) are among the very-long-chain PUFAs⁽¹⁵³⁾. The suggested AMD pathogenesis and progression mechanism is cumulative oxidative stress in the RPE. Because of their antioxidative and anti-inflammatory properties⁽¹⁵⁴⁾, marine-based omega-3 polyunsaturated fatty acids (EPA and DHA) in the retina were suggested to reduce the risk of AMD⁽¹⁵⁵⁾. Moreover, DHA is assumed to support retinal photoreceptor cell development because it is a major lipid component of the outer segments of the retina⁽¹⁵⁶⁾. Other suggested mechanisms are the inhibition of choroidal neovascularisation by omega-3 fatty acid, the interaction of triacylglycerol lipoproteins in RPE cells to delay AMD, structural replacement of omega-3 fatty acid with omega-6 fatty acid, induction of cellular responses, and mobilisation of cellular resistance to misfolded proteins and oxidative stress⁽¹⁵⁷⁾. In a prospective cohort study by Wu *et al.*, the hazard ratio (HR) for DHA compared with the extreme quintiles of intake for intermediate AMD was 0.78 ($p = 0.008$), and for EPA + DHA, it was 0.83 ($p = 0.03$)⁽¹⁵⁸⁾. Also, in a meta-analysis, a high dietary intake of omega-3 fatty acid was associated with a 38% reduction (OR 0.62) in the risk of late AMD⁽¹⁵⁹⁾. As a result of another

meta-analysis, higher omega-3 fatty acid intake was associated with a 14% (RR 0.86) and 29% (RR 0.71) lower risk of early and late AMD, respectively. In addition, the dose–response analysis revealed that each additional 1 g/d omega-3 fatty acid intake reduced the risk of early and late AMD by 6% and 22%, respectively. Intake of omega-3 fatty acid, EPA and DHA was inversely related to lower AMD risk⁽¹⁶⁰⁾. According to a prospective cohort study from the AREDS, individuals with the highest omega-3 fatty acid consumption had a 30% lower risk of central geographic atrophy and Neovascular AMD than others ((OR 0.65, $p = 0.02$) and (OR 0.68, $p = 0.02$), respectively)⁽¹⁶¹⁾. Similarly, in another report of AREDS, those who consumed the most EPA and EPA + DHA had a lower chance of developing central geographic atrophy, which is the next stage following bilateral drusen (OR 0.44 and OR 0.45, respectively)⁽¹⁶²⁾. Additionally, one of the primary sources of omega-3 fatty acid in the diet is the consumption of fish and fishery products, and one of the typical characteristics of them is being rich in omega-3 fatty acid, mainly EPA and DHA⁽¹⁶³⁾. Studies have examined the relationship between fish and fishery consumption and AMD^(124,145,158,164–166). As a result of a study by Christen *et al.*, women who consumed one or more fish per week, compared with those who consumed less than one serving per month, had an RR of AMD of 0.58 ($p = 0.001$). Dinu *et al.* conducted a meta-analysis study for fish consumption and AMD risk, and they determined a significant ($p < 0.05$) reduction of risk for total AMD, as well as for both early and late AMD (RR 0.82, RR 0.84 and RR 0.79, respectively)⁽¹⁶⁷⁾. Also, according to the results of a meta-analysis by Jiang *et al.*, the pooled RRs comparing extreme categories of fish intake were 0.79 and 0.71 for early and late AMD risk, and every 15 g/d of fish consumption was associated with a 13% and 14% lower risk of early and late AMD, respectively. In addition, fish intake was associated with a significantly reduced risk of AMD progression (RR 0.73)⁽¹⁶⁰⁾. Excessive amounts of omega-6 fatty acid and a high omega-6/omega-3 fatty acid ratio, as is found in Western diets, promote the pathogenesis of many chronic diseases, including cardiovascular, cancer and autoimmune diseases. In contrast, increased levels of omega-3 fatty acid exert suppressive effects⁽¹⁶⁸⁾. Mance *et al.* found that the omega-6/omega-3 fatty acid ratio was related to the development of neovascular AMD, and a decreased ratio protected against neovascular AMD⁽¹⁶⁹⁾. When omega-6 fatty acid and omega-3 fatty acid compete for the same enzymes in the cyclooxygenase and lipoxygenase pathways, a high intake of omega-6 fatty acids blocks the anti-inflammatory effects of omega-3 fatty acid. While omega-3 fatty acids produce anti-inflammatory and anti-angiogenic metabolites, omega-6 fatty acids produce pro-inflammatory metabolites⁽¹⁷⁰⁾.

At the ends of developing blood vessels, matrix metalloproteinases (MMPs) dissolve the extracellular matrix, essential for the steady growth of new blood vessels. MMPs govern numerous elements of angiogenesis and inflammation, and omega-3 fatty acid contributes to the control of MMPs⁽¹⁷¹⁾. Animal studies further show that the adiponectin pathway is one of the mechanisms through which omega-3 fatty acid prevents choroidal neovascularisation. Human retinal microvascular endothelial cells revealed that the adiponectin pathway reduces

MMP-2 and MMP-9 expression and ocular blood vessel development. Omega-3 fatty acid reduces MMP-2 and MMP-9 levels, phosphorylates AMPKa, activates the adiponectin pathway and inhibits the development of new blood vessels⁽¹⁷²⁾. One of the neurodegenerative diseases defined by an accumulation of misfolded proteins is AMD. Damaged proteins may adversely affect cellular function. NFE2L2, also known as NRF2, is a crucial gene regulator of genes that influence the redox status of cells. By making it easier for NRF2 activation and autophagy to work together, DHA makes RPE cells more resistant to damage from misfolded proteins and oxidative stress. An increase in protein levels and the nuclear translocation of NRF2 followed a brief increase in ROS due to physiological levels of DHA. Later, gene expression arrays were used to find that the NRF2-regulated protein Sequestosome-1 (SQSTM1) had more of it and that the expression of NRF2-regulated genes had increased. SQSTM1 selectively instructs misfolded ubiquitinated proteins to be destroyed in the lysosome⁽¹⁷³⁾. In animal models, DHA has been shown to make photoreceptors live longer and protect them from apoptotic signs such as broken photoreceptor nuclei and mitochondrial dysfunction⁽¹⁷⁴⁾. From a genetic point of view, increased intake of DHA significantly protected geographical atrophy progression among those with the *ARMS2/HTRA1*-associated genes with AMD-homozygous risk genotype⁽¹⁷⁵⁾. The Blue Mountain Eye Disease study revealed that weekly fish consumption decreased the risk of progression to late AMD among individuals with the homozygous risk genotype for *CFH*. However, there were only forty-seven late AMD cases for both geographical atrophy and neovascularisation combined, and they did not discover any associations with early AMD⁽¹⁷⁶⁾. The Rotterdam study found that people with the highest combined EPA and DHA intake had a lower chance of progressing to early AMD than those with the *ARMS2/HTRA1* homozygous risk genotype⁽¹²⁰⁾.

The maintenance of a proper balance between omega-6 fatty acid and omega-3 fatty acid is of greatest significance. Western diets, which tend to have elevated omega-6/omega-3 fatty acid ratios, may contribute to the development of AMD. The significance of maintaining an appropriate ratio is highlighted by the competition that occurs among these fatty acids for enzymes implicated in inflammatory pathways. It is consistently indicated that EPA and DHA, predominantly obtained from marine sources, as well as the consumption of fish, have a preventive role in mitigating the risk and advancement of AMD.

Dietary glycaemic index

The relationship between AMD and dietary carbohydrates is mainly related to the diet's glycaemic index (GI). Jenkins *et al.* proposed the concept of the GI in 1981 to describe how fast carbohydrates were absorbed after a meal⁽¹⁷⁷⁾. GI is calculated as the difference between the area under the glucose response curve after consuming 50 g of a test food and the area under the curve after consuming 50 g of a control food, such as white bread or glucose⁽¹⁷⁸⁾. The retina has one of the most extensive blood and nutrient supplies, including glucose. It depends on sufficient glucose transport from the systemic circulation to sustain its physiologic function, and retinal glucose reserves are insignificant

compared with glucose demand⁽¹⁷⁹⁾. However, due to age-related inefficiencies or improper metabolism, such as the production of advanced glycation end-products (AGEs) and their aftereffects, sustained high glucose levels or glucose spikes can cause serious health problems⁽¹⁸⁰⁾. The eye is particularly susceptible to harm from direct and indirect effects of persistently elevated blood glucose due to low capacity for cellular turnover, the limited roles of glucose transporters, and the high metabolic activity of the retina; therefore, AMD is linked to hyperglycaemia. The formation of AGEs and protein kinase C activation might cause the abnormal vasculature found in retinopathy⁽¹⁸¹⁾. Through the formation of AGEs, increased metabolism leads to the accumulation of reactive oxygen species and a decrease in glutathione, and protein kinase C activation leads to immunological hyperactivity. This increase in cellular glucose can cause cell damage and apoptosis⁽¹⁸²⁾. According to a cross-sectional analysis of AREDS baseline data, the quantity and glycaemic quality of dietary carbohydrates may be related to the prevalence of nuclear and cortical opacities; for cortical opacities of any severity, the OR in a comparison of the highest with the lowest quartile of consumption was 1.27 ($p=0.09$), and for all pure nuclear opacities it was 1.29 ($p=0.02$)⁽¹⁸³⁾. In a case-control analysis of the Nutrition and Vision Project (NVP), a substudy of Nurses' Health Study (NHS), women in the third tertile of dietary GI compared with those in the first tertile had an approximately 2.7-fold greater risk for early AMD, mainly pigment abnormalities ($p=0.01$). Contrarily, dietary carbohydrate intake was not significantly associated⁽¹⁸⁴⁾.

Similarly, in a study by Chiu *et al.*, eyes in the fourth and fifth quintiles of dietary GI had a significantly increased risk of drusen, geographic atrophy and neovascularisation compared with the eyes in the first quartile of dietary GI. Moreover, a clear association between dietary GI and the severity of AMD was observed ($p=0.001$)⁽¹⁸⁵⁾. In a 10-year follow-up study by Kaushik *et al.*, higher mean dietary GI was linked to a higher risk of developing early AMD in a comparison of quartiles 1 and 4 after adjustments for age, smoking, other risk factors and dietary components (relative risk (RR): 1.77, 95% CI: 1.13, 2.78, $p=0.03$), but the authors did not find a significant relationship between GI and late AMD⁽¹⁸⁶⁾. A recent case-control study showed a significant, direct correlation between daily GI, glycaemic load and insulin load on cataract risk⁽¹⁸⁷⁾. Animal studies also report the relationship between a high-GI diet and AMD^(188,189).

Based on available evidence, a higher dietary GI is believed to be associated with an increased risk of early AMD, the severity of AMD, and specific conditions linked to AMD, such as atrophy, neovascularisation and drusen. Therefore, in formulating dietary recommendations, avoiding high-GI foods may be considered among potential dietary strategies.

Dietary fibres

Dietary fibres (DFs) are carbohydrate polymers with three or more monomeric units⁽¹⁹⁰⁾. DF is classified into two types based on its solubility in water: soluble DF and insoluble DF. Soluble DF is the edible part of the plant that is resistant to digestion but can be partially or entirely fermented into short-chain fatty acids in the large intestine by colonic bacteria. Meanwhile, insoluble

DF passes unchanged through the digestive tract. While cellulose, some hemicellulose and lignin are examples of insoluble DF, pectin, gums, mucilage extracted from psyllium husk, glucan and fructans, as well as some hemicellulose, are examples of soluble DF⁽¹⁹¹⁾. One of the mechanisms explaining the relationship between DF intake and AMD is the gut microbiota. Dietary fibres not broken down by the body's enzymes in the upper gut are turned into short-chain fatty acids (SCFAs) by the microbiota in the cecum and colon. The main microbial fermentation products in the gut are acetate, propionate and butyrate⁽¹⁹²⁾. Aside from the physiological effects of SCFAs, the gut microbiome has been shown to influence multiple pathways involved in eye diseases. Increased gut permeability allows microbial products to be transported to the eye, where they can bind to receptors and signals ocular inflammation⁽¹⁹³⁾.

Furthermore, microbial metabolites have the potential to cross the blood-retina barrier and act as signalling molecules in the eye. Multiple molecules produced in the gut, including serotonin, have been linked to the severity of eye disease⁽¹⁸⁹⁾. In a study conducted by Agrón *et al.* with AREDS and AREDS2, a significant relationship was found between the risk of progression to large drusen and insoluble DF intake of the first to fourth and first to fifth quartiles ($p=0.011$ and $p=0.009$, respectively). In contrast, no significant relationship was found with soluble DF⁽¹⁴³⁾. Another study found no significant relationship between total DF intake and early AMD or its component lesions. However, cereal fibre consumption reduced the long-term risk of early AMD⁽¹⁸⁶⁾. In the case-control study of Tinkilic *et al.*, DF intake was lower in the advanced AMD group than in the control group ($p=0.006$)⁽¹⁹⁴⁾. Data from the Beaver Dam Eye Study also suggest that a high DF intake may be protective against nuclear cataracts⁽¹⁹⁵⁾ in contrast to the Blue Mountains Eye Study results of 5-year indecent cataracts⁽¹⁹⁶⁾.

The role of intestinal microbiota is considered crucial in understanding the connection between fibres and AMD. Metabolites generated by the microbiota are believed to influence pathways relevant to eye diseases. Further discussions on the relationship between intestinal microbiota and AMD, along with dietary strategies, will be explored in the following sections.

Phytochemicals

The use of particular nutrients and antioxidant supplements has decreased the possibility of progression from early AMD to late AMD in a comprehensive evaluation of trials published in the past 35 years⁽¹⁹⁷⁾. In addition, researchers are currently investigating the preventive and therapeutic roles of various phytochemicals, including carotenoids, flavonoids, polyphenols and anthocyanidins in the context of AMD⁽¹⁹⁸⁾. The protective effects of phytochemicals are attributed to several mechanisms, such as expanding and reducing reactive oxygen species, inhibiting factor- α and endothelial growth factor pathways, suppressing apoptosis and modulating inflammatory markers⁽¹⁹⁹⁾.

Carotenoids. Carotenoids are natural pigments in numerous fruits and vegetables, lending to their yellow, orange and red

hues. They can be classified into two groups: xanthophylls (lutein, zeaxanthin and meso-zeaxanthin) and carotenes (α -carotene, β -carotene and lycopene)⁽²⁰⁰⁾. Carotenoids are potent antioxidants that reduce oxidative stress in the macula and shield the RPE and choroid from light damage⁽²⁰¹⁾. Higher dietary β -carotene, lutein and zeaxanthin consumption are linked to a reduced risk of AMD progression⁽¹⁴³⁾. Higher plasma lutein levels were associated with a 37% reduced incidence of advanced AMD in the Alienor study, which included participants aged 73 or older⁽²⁰²⁾. Further details about the role of carotenoids can be found in this manuscript's 'Vitamin A and carotenoids' section.

Polyphenols. Dietary polyphenols represent many phytochemicals in fruits, vegetables, cacao powder, red wine, green tea and coffee. They possess antioxidant, anti-inflammatory, anti-allergic, antimicrobial and antiviral properties, contributing to overall health benefits⁽¹⁹⁹⁾. One of the polyphenols' prominent effects on health is its effects on vision. In addition, polyphenols help reduce oxidative stress, provide anti-inflammatory effects in RPE cells, and modulate interleukins and signalling pathways⁽²⁰³⁾. A study conducted with elderly Korean women from the Korea National Health and Nutrition Examination Survey (2010–2012) revealed that a higher dietary flavonol content was protective against the development of AMD⁽²⁰⁴⁾.

Studies on the therapeutic use of resveratrol, a polyphenol found in various foods such as blueberries, cocoa, peanuts, wine and grape juice⁽²⁰⁵⁾, have been growing in recent years^(206–209). Experimental studies have indicated that resveratrol may effectively target various pathways involved in the pathogenesis of age-related eye diseases, such as oxidative stress, inflammation, mitochondrial dysfunction, apoptosis or angiogenesis⁽²⁰⁶⁾. In a study by King *et al.*, it was observed that resveratrol (50 and 100 μ mol/l) inhibited intracellular oxidation and protected RPE cells from apoptosis. Therefore, it has been reported that resveratrol can decrease oxidative stress and hyperproliferation of RPE. This protective effect of resveratrol is attributed to its ability to inhibit the mitogen-activated protein kinase (MAPK) signalling cascade and the activities of extracellular signal-regulated kinases 1 and 2 (ERK 1/2)⁽²¹⁰⁾. In addition, sirtuin-1 (SIRT1) activation by resveratrol has ameliorated hydrogen peroxide-induced damage to lens epithelial cell morphology, promoting cell proliferation and inhibiting apoptosis⁽²¹¹⁾. In the case report of three patients treated with oral resveratrol (100 mg), extensive bilateral ocular structure and function improvements were observed over a long time⁽²⁰⁹⁾. Resveratrol treatment prevented increased intracellular reactive oxygen species and inflammatory marker production, lipofuscin expression and accumulation of carbonylated proteins⁽²¹²⁾. It is emphasised that resveratrol can achieve this effect by reconstructing the retinal structure, reducing the accumulation of lipofuscin, increasing choroidal thickness, shortening the recovery period of glare, enlarging the macular pigment volume, and improving both contrast sensitivity and visual function⁽¹⁹⁸⁾.

Furthermore, resveratrol has been reported to exert a protective effect against light-induced retinal degeneration by reversing the activation of retinal activating protein-1 and inhibiting light-induced up-regulation of SIRT1 activation⁽²¹³⁾

in addition to protecting RPE cells from apoptosis induced by autoimmune antibodies⁽²¹⁴⁾. Resveratrol contributes to the antioxidant defence system by increasing superoxide dismutase, glutathione peroxidase and catalase activities against hydrogen peroxide-induced cytotoxicity in human retinal D407 RPE cells⁽²¹⁵⁾. In addition, resveratrol suppresses the secretion of inflammatory cytokines, transforming growth factor β (TGF- β) and hypoxia-enhanced VEGF-A and VEGF-C secretion by human RPE cells. SIRT1, a significant modulator of resveratrol, suppresses hypoxia-induced factor-1 signalling, leading to decreased VEGF-A secretion⁽²¹⁶⁾. In human crystal epithelial cells, resveratrol also lessens the accumulation of intracellular reactive oxygen species (ROS) caused by hydrogen peroxide. It is emphasised that, due to its ability to restore vessels, resveratrol may also be beneficial for the microcirculation of the eye⁽¹⁹⁸⁾. Furthermore, resveratrol has been shown to protect RPE cells against acrolein-induced oxidative cytotoxicity by increasing mitochondrial bioenergy⁽²⁰⁸⁾.

A cohort study investigating the relationship between total dietary flavonoids and AMD found an independent and protective association between dietary flavonoid intake and the probability of developing AMD⁽²¹⁷⁾. Anthocyanins in blue, purple and red fruits, vegetables and flowers are water-soluble pigments belonging to the phenolic group and exhibit significant antioxidant and antimicrobial properties^(86,218). Anthocyanins are thought to be important for visual health due to their antioxidant effects. Their effects on visual health include improving visual function in patients with normal tension glaucoma, preserving photoreceptor cell function during retinal inflammation, reducing lens opacity accompanied by lower malondialdehyde (MDA) levels, suppressing cell death of lens epithelial cell line under oxidative stress induced by hydrogen peroxide, preventing retinal degeneration induced by *N*-methyl-*N*-nitrosourea, increasing ocular blood flow⁽²¹⁹⁾. In a study where anthocyanins from black soybean seed pods were taken by mouth for 4 weeks, it was found that they could protect retinal neurons from structural and functional damage caused by *N*-methyl-*N*-nitrosourea⁽²²⁰⁾. In addition, anthocyanins provided resistance to membrane permeability induced by the detergent-like effects of pyridinium bis-retinoid, light-induced damage to the cell on RPE cells⁽²²¹⁾.

Quercetin, another flavonoid found in fruits and vegetables that gives them their colour, is a powerful antioxidant commonly found in foods such as apples, onions and tea⁽²²²⁾. The study conducted by Cao *et al.* showed that quercetin altered the transcription of genes involved in the regulation of apoptosis in RPE cells exposed to oxidative stress induced by hydrogen peroxide⁽²²³⁾. In a rabbit study investigating the effect of quercetin on light-induced retinal damage, it was observed that quercetin effectively suppressed increased levels of oxidative stress markers and inhibited the production of inflammatory cytokines in the retina. Quercetin also regulated changes in the expression levels of apoptotic proteins and angiogenesis factors induced by photooxidative stress⁽²²²⁾. Furthermore, it modulates the activity of antioxidant enzymes, including phase II enzymes⁽²⁰³⁾. The protective effect of quercetin in the retina comes from its ability to directly remove ROS and its indirect anti-inflammatory, anti-apoptotic and antiangiogenic effects, as well

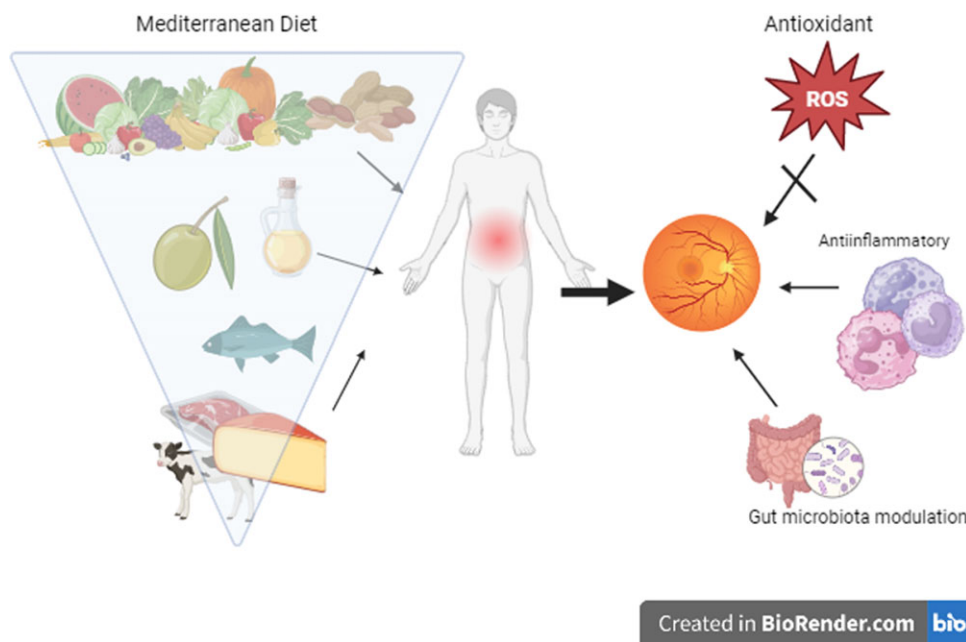


Fig. 3. The components of the Mediterranean diet and possible effects in AMD prevention/progression.

as its ability to reduce A2E photooxidation, lower methylglyoxal levels and stop the activation of enhanced end glycation product receptors⁽²²⁴⁾. In addition, quercetin appears to inhibit laser irradiation-induced choroidal neovascularisation and increase choroidal blood flow⁽¹⁹⁸⁾.

The beneficial effects of polyphenols on the lens of the eye can be summarised as inhibition of several inflammatory mediators, regeneration of rhodopsin, scavenging of reactive oxygen species, reduction of the formation of advanced glycation end products, inhibition of aldose reductase and enhancement of ocular blood flow⁽¹⁹⁸⁾. Figure 3 summarises the mechanisms by which phytochemicals are thought to be involved in preventing AMD development. Saffron^(224,225), ginkgo⁽²²⁶⁾, blueberry and bilberry^(227,228), goji berry⁽²²⁹⁾, and curcuma or turmeric^(230,231) are among the herbal products most extensively studied about macular degeneration. The effectiveness of these plants may be attributed to their phytochemical constituents⁽¹⁹⁸⁾. Consumption of foods rich in these phytochemicals may offer protection against AMD; however, further research is needed to establish more substantial evidence. Phytochemicals stand out for their potential preventive and therapeutic roles in AMD by reducing oxidative stress, inflammation and apoptosis. Although these phytochemicals protect against AMD and have promising therapeutic effects, more research is needed for more robust evidence. However, based on the data we have, it is clear that adding foods rich in phytochemicals to the diet and ensuring nutritional diversity is very important for eye health.

Biotics

The gut microbiome plays a substantial role in human health by influencing the development of various chronic diseases, including gastrointestinal disorders and metabolic conditions⁽²³²⁾.

The presence of diverse gut bacteria has beneficial effects on health by producing short-chain fatty acids, essential in maintaining lipid homeostasis and reducing inflammation through the fermentation of dietary fibre⁽²³²⁾. Recent evidence suggests a connection between the gut and the eyes, known as the gut–eye axis, where an imbalance in gut microbiota, known as gut dysbiosis, may contribute to the onset and progression of AMD⁽²³³⁾. Differences in taxonomic and functional characteristics of the human microbiome are reported between people with AMD and healthy controls⁽²³⁴⁾. This emerging field of research indicates that the gut microbiome could significantly impact the development and management of AMD. In an AMD mouse model, a high-fat diet worsened laser-induced choroidal neovascularisation and led to alterations in the composition of the gastrointestinal microbiome⁽²³⁵⁾. Mice on a high-fat diet showed a higher prevalence of Firmicutes and Proteobacteria, while those on a regular diet had a higher prevalence of Bacteroidetes.

Similarly, another study in mice compared a high-GI diet and a low-GI diet and found that the high GI diet-induced AMD symptoms in the retina while switching to the low-GI diet either halted or reversed these symptoms⁽¹⁸⁹⁾. In addition, the high-GI diet was associated with abundant Firmicutes and Proteobacteria, specifically within the Clostridia and Bacilli classes. In contrast, the low-GI diet promoted a higher prevalence of Bacteroidetes and Erysipelotrichia^(189,236). In studies investigating the association between the gut microbiome and AMD in humans, specific microbial changes have been observed in patients with AMD compared with controls. The genera *Anaerotruncus* and *Oscillibacter* and the species *Ruminococcus torques* and *Eubacterium ventricose* were found to be more abundant in patients with AMD. At the phylum level, patients with AMD had a higher relative abundance of Firmicutes than Bacteroidetes⁽²³⁷⁾. At the phylum level, patients with AMD had a higher relative abundance of Firmicutes compared with

Bacteroidetes⁽²³⁷⁾. Another study identified that the genus *Oscillibacter* and species *Bacteroides* were more prevalent in healthy controls, whereas the Negativicutes class was more abundant in patients with AMD. Negativicutes showed the highest potential as a possible biomarker for detecting AMD in patients⁽²³⁸⁾.

Metabolic processes have also been found to differ in patients with AMD. In the gut microbiota of patients with AMD, genes related to the fatty acid elongation pathway were down-regulated. In contrast, genes related to L-alanine fermentation, glutamate degradation and arginine biosynthesis were up-regulated⁽²³⁷⁾. Depleting glutamate, an excitatory neurotransmitter for the retina and brain, may lead to insufficient neurotransmission in the retina, which could explain the connection between increased glutamate breakdown and patients with AMD⁽²³⁹⁾. Additionally, higher ornithine levels have been observed in patients with choroid and retinal atrophy due to decreased ornithine-ketoacid aminotransferase activity. This suggests that arginine may play a crucial role in the development of retinal degeneration⁽²⁴⁰⁾. A mice study found that low GI diets reduced the accumulation of C3-carnitine in the retina, plasma or urine, as well as long-chain polyunsaturated lipids and their peroxidation end products⁽¹⁸⁹⁾. Serotonin, particularly from microbial cometabolites, is suggested to have anti-AMD potential⁽¹⁸⁹⁾.

Additionally, a positive correlation between harmful inflammation and CFH in a study suggests that the gut microbiota may contribute to the pathogenesis of AMD through the dysregulated regulation of the complement system⁽²³⁸⁾. These findings highlight the potential role of specific gut microbial compositions and metabolic pathways in the pathogenesis of AMD. Further research is needed to understand the mechanisms better and explore the therapeutic potential of modulating the gut microbiome for AMD prevention and treatment.

Recent research has shed light on the concept of an intestinal–eye axis, where intestinal dysbiosis plays a significant role in the development and progression of macular degeneration⁽²³³⁾. Dietary factors can influence the composition of the gut microbiota, which regulates the immune system and inflammation⁽²⁴¹⁾. Furthermore, the gut microbiota may have an indirect impact on ocular health through its influence on insulin sensitivity and obesity⁽²⁴²⁾. Bacterial translocation from the gut to the eye is one possible mechanism for the relationship between the gut microbiota and AMD⁽²⁴³⁾. Andriessen *et al.* (2016) state that intestinal dysbiosis can lead to increased intestinal permeability and chronic low-grade inflammation. This dysbiosis can result in elevated production of pro-inflammatory cytokines such as IL-6, IL-1, TNF and VEGF, exacerbating AMD pathological angiogenesis⁽²³⁴⁾. Intestinal dysbiosis can also impair immune responses and disrupt mucosal barrier function, allowing pathogenic microbes and their metabolites to enter the bloodstream. This bacterial translocation can induce local and systemic inflammation, potentially contributing to the development of AMD⁽²⁴⁴⁾. However, it is still unclear whether mucosal inflammation is the cause or consequence of dysbiosis⁽²⁴⁰⁾. The potential of microbial substances to translocate through the intestinal wall and bind to receptors in the eye to signal ocular inflammation is

increased^(235,244). Mice with intestinal dysbiosis induced by a high-fat diet had a twofold increase in microglia and macrophages within CNV lesions⁽²³⁵⁾. Researchers did high-throughput RNA sequencing on germ-free (GF) mice to look at the changes in gene expression caused by a high-fat diet (HFD) in the RPE and choroid. The study revealed that HFDs could lead to transcriptional alterations in the RPE and choroid tissue, even without gut microbiota. A total of 649 differentially expressed genes (DEGs) were identified in the HFD group, with 616 genes showing up-regulation and 33 genes showing down-regulation at the transcriptional level. Through Gene Ontology (GO) analysis of the DEGs, HFD induced up-regulation of angiogenesis, the immune response and inflammatory processes. Furthermore, ECM binding, ECM structural components and heparin binding were altered⁽²⁴⁵⁾.

In the same way that they can impact the bioavailability of numerous micronutrients, such as folic acid, vitamin B₁₂ and iron, gut microorganisms can also affect the bioavailability of carotenoids and zinc, which are protective against AMD⁽²⁴⁰⁾. These findings suggest that the gut microbiota and its metabolites, including those impacted by SCFAs, can influence the development and progression of AMD by modulating intestinal permeability, inflammation and nutrient bioavailability. SCFAs may positively affect AMD by increasing intestinal epithelial integrity and reducing systemic inflammation⁽²⁴⁰⁾.

Modulating the human gut microbiota is a promising strategy for promoting overall health and preventing and treating various diseases. Indeed, the modulation of the gut microbiota through dietary adjustments or probiotic intake holds potential as a treatment option in conditions with an inflammatory component like AMD. These approaches aim to maintain immunological homeostasis, promote the production of beneficial metabolites by gut bacteria, and reduce complement activation⁽²³⁴⁾. Various studies have demonstrated that specific dietary fibres can significantly affect the human gut microbiota's abundance, diversity and metabolism^(246–249). The systematic review of human intervention studies on the effects of intact cereal fibres and their active subfractions on gut microbiota composition in healthy adults included forty-two studies⁽²⁴⁶⁾. Thirty-nine studies reported increased microbiota diversity and/or abundance after consuming intact cereal fibre. Based on the findings, it has been determined that an increase of 6–8 g in wheat fibre intake can significantly affect the gut microbiota^(246,250). One of the proposed mechanisms underlying the protective effects of prebiotic cereal dietary fibres is their fermentation by the colonic microbiota. During this fermentation process, the gut microbiota produces several metabolic byproducts, including acetate, propionate and butyrate, which are SCFAs. The addition of different grains to the diet has been found to have varying effects on the concentrations of acetate, butyrate and propionate. When considering acetate, its concentration tends to increase with the consumption of various grains. As for butyrate, its concentration specifically increases with the addition of rice and oats, and similarly, propionate concentrations tend to increase with the addition of wheat or sorghum to the diet⁽²⁴⁷⁾. These results show that different grains can have different effects on the production of SCFAs by the gut microbiota and that the changes in the concentrations of acetate, butyrate and propionate depend on

which grains are eaten. Overall, the fermentation of the prebiotic effects of cereal dietary fibres by the colonic microbiota and the production of SCFAs contribute to the anti-inflammatory effects and modulation of glucose and lipid metabolism, thereby playing a role in the promotion of gut health and overall wellbeing.

The role of omega-3 fatty acids is essential in modulating the gut microbiota. The gut microbiota, omega-3 fatty acids and host immune cells work together to maintain the integrity of the gut wall⁽²⁵¹⁾. Clinical studies have shown that omega-3 fatty acids can reduce the Firmicutes/Bacteroidetes ratio and decrease the levels of *Coprococcus* and *Faecalibacterium*. Also, *Bifidobacterium*, *Lachnospira*, *Roseburia* and *Lactobacillus*, which are types of bacteria that make butyrate, are more common when there are more omega-3 fatty acids⁽²⁵²⁾. Furthermore, omega-3 PUFAs can reduce the Firmicutes/Bacteroidetes ratio and decrease the levels of *Coprococcus* and *Faecalibacterium*. Also, omega-3 fatty acids have been linked to a rise in the number of bacteria that make butyrate, such as *Bifidobacterium*, *Lachnospira*, *Roseburia* and *Lactobacillus*. This suggests that omega-3 PUFAs promote the growth and activity of butyrate-producing bacteria, which are essential for gut health. Additionally, a significant correlation was observed between plasma levels of omega-3 PUFAs and the *Lachnospiraceae* family, known for its ability to produce SCFAs such as butyrate⁽²⁵²⁾. These findings highlight the interaction between omega-3 PUFAs, the gut microbiota and SCFA production, emphasising the importance of a balanced gut microbial community and the potential role of omega-3 PUFAs in promoting gut health and overall wellbeing.

Probiotics are one of the issues addressed to ensure intestinal microbiota modulation. In a randomised, double-blind, placebo-controlled study, participants aged between 50 and 85 years with AMD took either a probiotic capsule or a placebo daily for 8 weeks⁽²⁵³⁾. The results showed that probiotic supplementation led to increased plasma total antioxidant capacity and HDL-cholesterol levels while reducing malondialdehyde levels, indicating a decrease in oxidative stress and improved antioxidant status. However, no significant effects were observed on other clinical indicators or metabolic profiles⁽²⁵⁴⁾. In addition, specific strains of lactic acid bacteria, such as *Lactobacillus paracasei* KW3110, have shown promise in reducing inflammation and protecting against ocular diseases. In both mouse and human studies, *L. paracasei* KW3110 has been found to activate macrophages that reduce inflammation⁽²⁵⁵⁾. In addition, taking *L. paracasei* KW3110 was linked to less inflammation and better activation of M2 macrophages in a study on people with eye diseases caused by visual display terminal (VDT) load.

Additionally, in a mouse model of light-induced retinopathy, *L. paracasei* KW3110 supplementation decreased inflammation and protected against photoreceptor degradation, suggesting its potential for protection against retinal disorders⁽²⁵⁴⁾. These results suggest that taking probiotics, especially certain strains like *L. paracasei* KW3110, may help protect against inflammation and oxidative stress in AMD and other retinal diseases that are similar to it. However, further research is needed to understand the mechanisms and establish optimal treatment protocols fully. These results suggest that taking

probiotics, especially certain strains like *L. paracasei* KW3110, may help protect against inflammation and oxidative stress in AMD and other retinal diseases that are similar to it. However, further research is needed to fully understand the mechanisms and establish optimal treatment protocols⁽²⁵⁵⁾.

The association between intestinal microbiota imbalance (dysbiosis) and the initiation and progression of age-related macular degeneration (AMD) takes centre stage, introducing the concept of the gut–eye axis. Studies reveal alterations in the composition of intestinal microbiota and metabolic processes among individuals with AMD. Promising developments in AMD treatment include dietary adjustments (such as increasing omega-3 fatty acids and reducing the glycaemic index), incorporating prebiotics and probiotics, and modulating the intestinal microbiota through postbiotics. To better understand the role of the microbiome and the potential benefits of probiotics, prebiotics and postbiotics in AMD, further randomised clinical trials with larger sample sizes are needed. These studies would help to assess the effectiveness and safety of interventions that target the gut microbiome in patients with AMD. Conducting more research to unravel the specific mechanisms through which gut dysbiosis influences AMD is essential. This will provide insights into the underlying biological processes and help identify therapeutic strategies that directly target the gut microbiome to prevent and treat AMD. Continued investigation in this area holds great potential for advancing our understanding and management of this complex eye condition.

Dietary patterns

In the preceding sections of our manuscript, we discussed individual nutrients' effectiveness on AMD. However, assessing the overall diet in conjunction with specific nutritional elements is crucial. Previous studies primarily focused on specific foods, food groups and nutrient intake using data from food frequency questionnaires or food consumption records. More recent studies have also examined general dietary patterns⁽²⁵⁶⁾. This concept emphasises that foods supply essential nutrients to the body and contain numerous compounds that interact synergistically⁽²⁵⁷⁾. These interactions often occur when these molecules are present in their natural matrices. More than merely assessing individual nutrients or components is required to understand the impact of a diet on health. When evaluating the impact of diet on health and disease, it is essential to consider all dietary patterns rather than focusing solely on certain food groups or nutrients⁽²⁵⁸⁾. Diet is a multifaceted lifestyle behaviour that influences the consumption of particular foods due to cultural, geographic and economic factors⁽²⁵⁸⁾. Furthermore, while exogenous supplementation may appear practical, adherence to a healthy diet is crucial. This suggests that the risk of AMD can be modified through diet alone without exogenous supplementation⁽²⁵⁹⁾.

Numerous studies have examined the relationship between diet and AMD^(202,258,260,261). Evaluation of baseline AREDS dietary data revealed two main components, which the researchers referred to as Oriental and Western patterns. A notable intake of vegetables, legumes, fruits, whole grains, tomatoes and seafood distinguished the Oriental dietary pattern. In contrast, the Western dietary pattern was characterised by an elevated

consumption of red meat, processed meat, high-fat dairy products, French fries, refined grains and eggs⁽²⁶²⁾. As a result, the Oriental pattern has been linked with considerably lower early and advanced AMD rates.

In contrast, the Western pattern was related to significantly higher rates of early and advanced AMD. According to the Melbourne Collaborative Cohort Study, a diet high in grains, fish, chicken, vegetables and nuts and low in red meat has been linked to a lower prevalence of late AMD⁽²⁶³⁾. The Coimbra Eye Study and the Korea National Health and Nutrition Examination Survey found that higher vegetable, fruit and nut consumption was associated with a statistically significant lower risk of developing AMD^(264,265). This correlation is likely because fruits and vegetables, particularly dark-green leafy varieties, are rich in carotenoids (e.g. lutein and zeaxanthin), and nuts are rich in fatty acids⁽²⁶⁶⁾. These nutrients support a robust immune system, reduce oxidative stress and prevent retinal inflammation. However, in the Atherosclerosis Risk in Communities (ARIC) study, no significant association was observed between dietary patterns and any incident or early AMD events. However, it was reported that the Western pattern may be a risk factor for the development of late AMD⁽²⁶⁷⁾. Similar to this study, the Irish Nun Eye Study observed no association between a diet model and the risk of AMD⁽²⁶⁸⁾. The complexity of DP composition, geographic variations in dietary intake, genetic factors and AMD definitions can be confounding factors limiting the association between diet and AMD outcomes. The low prevalence of AMD in the Irish Nun Eye study population, their relatively good health for their age, and their restricted dietary intake may have limited the statistical power to detect an association between diet and AMD⁽²⁶⁸⁾. The presence of certain factors, such as variations in geographic dietary patterns, genetic variations, and differences in how AMD is classified, could introduce confusion and limit the ability to detect clear associations with dietary outcomes. Furthermore, the study's authors indicated that the relatively low prevalence of AMD in the study population might not be attributed to AMD itself but rather to the participants' overall good health and adherence to a restricted diet. It is worth noting that the study's statistical power may be limited in detecting specific associations⁽²⁶⁸⁾.

Advanced AMD is linked to total diet quality, according to a study using the Healthy Eating Index (HEI) and Alternative Healthy Eating Index (AHEI)⁽²⁶⁹⁾. In case-control research examining the link with advanced AMD, HEI, used to analyse the relationship of diet with health, was found to be protective⁽²⁶⁹⁾. The components of trans fat intake and the proportion of polyunsaturated to saturated fats are AMD-protecting characteristics of alternative HEI. In the Carotenoids in Age-Related Eye Disease Study, the Healthy Eating Index (HEI) 2005 score was calculated to assess dietary quality. It was observed that individuals in the highest quintile of the index had a 46% lower risk of developing early AMD compared with those in the lowest quintile⁽²⁷⁰⁾.

The Mediterranean diet stands out among the discussed dietary models due to its well-documented health benefits. This dietary pattern is characterised by high consumption of plant-based foods, moderate intake of fish and wine, limited consumption of dairy products and meat, and the use of

monounsaturated fatty acids (MUFAs), such as olive oil, as the primary source of fat⁽²⁷¹⁾. Multiple studies have shown that greater adherence to the Mediterranean diet is associated with a decreased risk of developing AMD and a lower likelihood of disease progression^(256–258,264). In addition, a comprehensive analysis of eight human observational studies conducted in 2022 confirmed that increased adherence to a Mediterranean eating pattern is linked to a decreased risk of acquiring AMD and experiencing disease progression⁽²⁵⁷⁾.

Similarly, a systematic review published in 2022 summarised research spanning 35 years and found moderately specific evidence supporting the association between adherence to a Mediterranean diet and a decreased risk of progressing from early to late AMD⁽¹⁹⁷⁾. The Coimbra Eye Study conducted in Portugal also reported that high adherence to the Mediterranean diet was protective against the development of AMD, with fruit consumption specifically identified as having a potential protective role⁽²⁶⁴⁾. Figure 3 shows the components of the Mediterranean diet and their possible roles in AMD prevention and progression.

There are indeed interactions between genes and nutrients in AMD. The Mediterranean diet is associated with a reduced risk of late AMD among individuals with protective alleles of the *CFH* gene⁽²⁷²⁾. The *CFH* gene is one of the essential genes implicated in AMD. Higher adherence to the Mediterranean diet has been associated with a decreased risk of developing advanced AMD, and genetic susceptibility may play a role in this association⁽²⁷¹⁾. In the AREDS study, when accounting for various factors, a high alternate Mediterranean Diet (aMeDi) score was significantly associated with a decreased risk of progressing to advanced AMD. However, this association was not observed in individuals with homozygous risk alleles ©⁽²⁷¹⁾.

On the other hand, people with the complement factor H Y402H non-risk (T) allele had a significantly lower risk of getting advanced AMD if they had a higher aMeDi score⁽²⁷¹⁾. According to the European Eye Study, following the Mediterranean diet reduced the risk of wet AMD, regardless of the presence of the *CFH* risk allele. At the same time, no significant correlation was observed with early AMD⁽²⁵⁸⁾. It should be noted that the AREDS study initially included individuals with intermediate AMD, which may have an overrepresentation of the *CFH* risk allele, and the presence of the *CFH* protective allele in individuals without the *CFH* risk allele could be a factor contributing to these findings⁽²⁷²⁾. Using data from the Age-Related Eye Disease database, researchers looked at how the size of drusen changed over time and how it related to genetic susceptibility and following an alternative Mediterranean diet. They found that genetic susceptibility was linked to drusen growth on its own. Additionally, it has been reported that moderate to high adherence to the alternative Mediterranean diet score tends to reduce the risk of drusen growth⁽²⁰²⁾.

Additionally, the precise mechanism by which the Mediterranean diet influences AMD still needs to be fully understood⁽²⁵⁶⁾. It is challenging to determine whether the effect is directly attributable to the specific foods included in the diet, indirectly attributed to a reduction in the consumption of unhealthy foods, or a combination of both. Cross-sectional and

prospective studies conducted in population-based and clinical cohorts, as well as in different geographic regions, have consistently shown that a diet high in fruits, vegetables, legumes and fish while avoiding unhealthy foods like red meat and moderate alcohol intake may help prevent AMD⁽²⁵⁶⁾. The protective effects of the Mediterranean diet against the pathogenesis and progression of AMD are attributed to its rich antioxidant and anti-inflammatory components. It is logical to assume that the Mediterranean diet emphasises the consumption of food groups high in vitamins C and E and rich in antioxidants like lutein and zeaxanthin⁽²⁵⁷⁾. Carotenoids exhibit a protective effect against AMD in the retina through two mechanisms. Firstly, it acts as a blue light filter, absorbing harmful blue light and reducing the risk of light-induced damage. Secondly, lutein functions as an antioxidant, counteracting free radicals and reactive oxygen species, thereby reducing oxidative stress and protecting the retina from damage⁽²⁷³⁾.

The potential preventive effect of the Mediterranean diet on AMD is likely mediated through the consumption of vegetables, fruits and nuts, as these food groups provide significant levels of antioxidants⁽²⁶⁴⁾. In addition to vitamins and carotenoids, various fruits and vegetables also contain phytochemicals that may contribute to the observed associations between dietary intake of these nutrients and a lower prevalence of AMD⁽²⁷²⁾. Furthermore, it is now widely recognised that certain vegetables and diets high in fruits and vegetables promote a healthy gut microbiome⁽²⁷²⁾. Higher adherence to the Mediterranean diet has been associated with specific changes in the gut microbiota composition⁽²⁷⁴⁾. Individuals with greater adherence to the Mediterranean diet have been shown to have higher SCFA levels and an increased abundance of Bacteroidetes. Conversely, reduced adherence to the Mediterranean diet has been related to an elevated ratio of Firmicutes to Bacteroidetes (F/B ratio)⁽²⁷⁴⁾. An imbalance in the F/B ratio has been implicated in various health conditions, including obesity and metabolic disorders. Also, a Mediterranean diet with more nuts and legumes has been shown to boost the growth of good bacteria, which is linked to positive changes in the way the gut microbiome works, including more short-chain fatty acid production, less secondary bile acids and fewer inflammation markers⁽²⁷⁴⁾. In addition, a study on the Korean population revealed that a diet rich in legumes may protect against age-related macular degeneration⁽²⁶⁰⁾. These results suggest that the Mediterranean diet, which focuses on plant-based foods, whole grains, legumes and olive oil, may help create a healthier gut microbiota by increasing SCFA production and keeping the number of Firmicutes to Bacteroidetes healthy.

The positive effects of the Mediterranean diet on health can be attributed in part to the great use of olive oil used in this diet. Olive oil is a rich MUFA source and contains polyphenols, which possess various beneficial properties such as antioxidant, anti-inflammatory, antithrombotic and antimicrobial properties⁽²⁷⁵⁾. The relationship between MUFA intake and AMD has yielded inconsistent findings, suggesting that the protective effects of olive oil may be attributed to its polyphenol content⁽¹⁴⁷⁾. Olive oil contains soluble phenolic compounds like oleuropein, hydroxytyrosol, tyrosol, and oleocanthal, recognised for their antioxidant and anti-inflammatory

properties⁽¹⁷⁾. Nonetheless, the available evidence suggests that the presence of polyphenols in olive oil plays a significant role in its protective effects against AMD. In the Alienor study, which focused on the elderly population, the associations between olive oil use and the prevalence of AMD were examined. The results showed that regular olive oil use was significantly associated with a reduced risk of late AMD, but no significant association was found with early AMD. Further research is needed to understand better the specific mechanisms by which olive oil may impact AMD development and to explore its potential benefits in preventing the early stages of the disease⁽¹⁴⁷⁾.

The consumption of fish, an excellent source of omega-3 fatty acids, is vital for the Mediterranean diet. omega-3 fatty acids have also been shown to play a significant role in this protective effect for AMD. The high content of omega-3 fatty acids in the retina may explain the association between fish consumption and AMD progression⁽²⁶⁰⁾. Also, omega-3 fatty acids may be protective because higher levels of docosapentaenoic acid in the blood have been linked to a higher macular pigment optical density⁽²⁷⁶⁾. In addition, a nationwide survey conducted in Korea found that more frequent fish consumption was associated with a lower risk of developing early AMD⁽²⁶⁰⁾.

Other dietary patterns or scores, such as the dietary inflammatory index or GI, which could potentially be important for AMD, have not received as much attention as the Mediterranean diet due to the need for more detailed dietary data and new prospective cohort studies⁽²⁵⁶⁾. However, some studies have explored the association between these dietary patterns and AMD. For example, according to the Tsuruoka Metabolomic Cohort Study findings, individuals who followed a variable staple diet characterised by a higher intake of bread and noodles but a lower intake of rice had a reduced prevalence of intermediate AMD⁽²⁶¹⁾. Additionally, a high GI diet has been found to significantly increase the risk of AMD progression compared with a low-GI diet. Therefore, adopting a low-GI diet and reducing the consumption of refined carbohydrates may be advisable for preventing AMD⁽²⁷⁷⁾.

Calorie restriction (CR) is one of the dietary strategies being examined to prevent age-related functional decline, including ocular illnesses⁽²⁴²⁾. A study with Brown Norway mice examined the effect of 40% energy restriction on retinal ageing. It was found that the group on a calorie-restricted diet had significantly higher outer nuclear layer (ONL) cell densities, ONL height and retinal thickness than the group on an *ad libitum* diet⁽²⁷⁸⁾. In addition, CR was associated with higher peripheral INL cell density and thickness. Another study examining the effect of 40% CR on photoreceptor cell loss in Fischer 344 rodents found that the CR group lost more photoreceptor cells, especially in the retina's centre. This suggests that the loss of photoreceptor cells is caused by light. Furthermore, the detrimental effect of intense light on photoreceptor cell density was more pronounced in the CR group. The authors hypothesise that calorie restriction may affect circadian activity, which could explain its apparent inability to delay retinal ageing in albino rats⁽²⁷⁹⁾. It has been suggested that the protective function of photoreceptors may vary among rat species⁽²⁴²⁾. A study with male Wistar rats found that reducing the amount of food eaten or the number of calories in the food led to a significant decrease in the amount of RPE

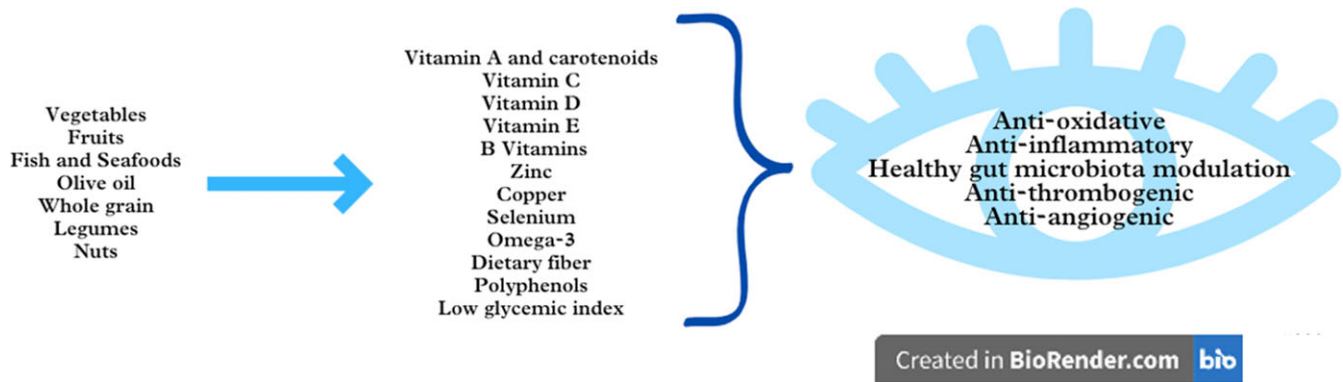


Fig. 4. Summary of the relationship between food groups/components and AMD.

lipofuscin⁽²⁸⁰⁾. Due to the challenges of implementing calorie restriction as a disease prevention or treatment strategy, intermittent fasting has been developed to mimic the benefits of calorie restriction with less stringent practices⁽²⁴²⁾. Intermittent fasting is currently attracting much interest due to its ability to defend against several systemic diseases, such as eye, cardiovascular and even metabolic disorders⁽²⁵⁵⁾. Every-other-day fasting (EODF) has been suppressing retinal degeneration without changing intraocular pressure in a glaucoma mouse model⁽²⁸¹⁾. The improvement of visual impairment with EODF highlights its neuroprotective effect. This protective effect is related to the up-regulation of blood β -hydroxybutyrate levels and increased histone acetylation in the retina, which reduce oxidative stress levels. After rats were injured, dietary restriction helped their retinas improve by lowering oxidative stress and increasing the activity of an enzyme involved in oxidative phosphorylation⁽²⁸²⁾. Only one human study evaluated the association of intermittent fasting with AMD. According to a cross-sectional study from Korea, adults over 70 years of age who are obese and live in urban areas have a significantly lower risk of AMD when they practice intermittent fasting by skipping breakfast⁽²⁵⁵⁾. Interventional prospective studies are needed to confirm the effect of intermittent fasting on AMD.

When assessing the impact of foods and nutrients on health, it is crucial to focus on general nutritional patterns rather than individual foods alone. Among the dietary models under consideration, the Mediterranean diet stands out for its protective effects against AMD. Essentially, the Mediterranean diet encompasses a combination of foods and nutritional elements discussed in preceding sections of the article, believed to be protective against the formation or progression of AMD. Embracing the Mediterranean diet, recognised as one of the healthiest dietary models globally, would be not only logical in terms of overall health effects but also specifically beneficial for AMD. Nevertheless, when delving into dietary patterns and nutritional elements, it is imperative to consider the interplay of genetics with diet and explore potential interactions influencing the development of AMD. In this context, examining nutrition individually and adopting a nutrigenomic approach can prove to be highly valuable.

Conclusions

In this modern world, where we are getting older and exposed to oxidative stress daily, AMD remains an essential eye disease.

Some nutrients have long been associated with eye health. Less well-known roles of diet, nutrients, certain bioactive compounds and beneficial biotics appear specific to AMD. At this point, all kinds of nutrients, non-nutrient compounds and nutritional models that can combat oxidative stress and inflammatory situations, which form the basis of the pathophysiology of AMD, come to the fore. On the other hand, when the studies on this subject are examined, it can be easily seen that most of them are not RCTs; instead, they are primarily observation based and have model study results. In addition, studies are focused on supplementation rather than nutrients found in natural foods. This may mislead us about the doses that can be effective, especially for AMD.

In addition to being more cost-effective than clinical or pharmaceutical interventions, diet-based preventive measures are promising; however, due to the lack of clear guidelines in this area, the variability in dietary recommendations provided by physicians, and the need for more consensus between the recommendations and the actual dietary practices of patients with AMD, there is a need for collaboration between physicians and dietitians and for the dietitian support for AMD patients. In light of the information gathered so far, it is advisable to consume high amounts of vegetables, especially incredibly dark-green leafy vegetables and fruits, to prevent the progression of AMD. Besides, choosing low-GI foods instead of high-GI foods and increasing fish and seafood may also be beneficial. Furthermore, regularly consuming nuts (for example, peanuts and walnuts) is recommended as a part of a healthy diet (Fig. 4.). As a dietary model, adherence to the Mediterranean diet, which incorporates all these components, can be recommended, and the Mediterranean-style diet can be considered a reliable diet style for AMD and all kinds of diseases. Moreover, the modulation of the gut microbiota through dietary adjustments with biotics holds potential as a treatment option in conditions with an inflammatory component like AMD. Future studies should be conducted to develop personalised therapeutic and preventive approaches that also consider the interaction between nutrition and genetics.

Acknowledgements

Figures were created with BioRender.com.

Financial support

This research received no specific grant from any funding agency, commercial or not-for-profit sectors.

Competing interests

The authors declare no conflict of interest.

Authorship

Conceptualisation, D.A. and E.K.; writing – original draft preparation, D.A., E.K., N.E.G. and S.A.; writing – review and editing, D.A.; visualisation, N.E.G. and S.A.; supervision, D.A. All authors have read and agreed to the published version of the manuscript.

References

- [1] Gheorghe A, Mahdi L & Musat O (2015) Age-related macular degeneration. *Rom J Ophthalmol* **59**, 74–77.
- [2] Mitchell P, Liew G, Gopinath B, *et al.* (2018) Age-related macular degeneration. *Lancet* **392**, 1147–1159.
- [3] Wong WL, Su X, Li X, *et al.* (2014) Global prevalence of age-related macular degeneration and disease burden projection for 2020 and 2040: a systematic review and meta-analysis. *Lancet Glob Health* **2**, e106–e116.
- [4] Pennington KL & DeAngelis MM (2016) Epidemiology of age-related macular degeneration (AMD): associations with cardiovascular disease phenotypes and lipid factors. *Eye Vis* **3**, 1–20.
- [5] Koçyiğit E & Nilüfer A (2022) The role of omega-3 and antioxidant nutrients in age-related macular degeneration: a review article. *Clin Exp Health Sci* **12**, 548–555.
- [6] Hernández-Zimbrón LF, Zamora-Alvarado R, Velez-Montoya R, *et al.* (2018) Age-related macular degeneration: new paradigms for treatment and management of AMD. *Oxid Med Cellular Long* **2018**, 8374647.
- [7] Nashine S (2021) Potential therapeutic candidates for age-related macular degeneration (AMD). *Cells* **10**, 2483.
- [8] Arroyo JG (2020) Age-related macular degeneration: treatment and prevention. *UpToDate* **1**, 1–12.
- [9] García-Layana A, Cabrera-López F, García-Arumí J, *et al.* (2017) Early and intermediate age-related macular degeneration: update and clinical review. *Clin Int Aging* **12**, 1579–1587.
- [10] Stahl A (2020) The diagnosis and treatment of age-related macular degeneration. *Disch Arztebl Int* **117**, 513.
- [11] Flores R, Carneiro Â, Vieira M, *et al.* (2021) Age-related macular degeneration: pathophysiology, management, and future perspectives. *Ophthalmologica* **244**, 495–511.
- [12] van Lookeren Campagne M, LeCouter J, Yaspan BL, *et al.* (2014) Mechanisms of age-related macular degeneration and therapeutic opportunities. *J Pathol* **232**, 151–164.
- [13] Bernstein PS, Li B, Vachali PP, *et al.* (2016) Lutein, zeaxanthin, and meso-zeaxanthin: the basic and clinical science underlying carotenoid-based nutritional interventions against ocular disease. *Prog Retin* **50**, 34–66.
- [14] Carneiro Â & Andrade JP (2017) Nutritional and lifestyle interventions for age-related macular degeneration: a review. *Oxid Med Cell Longev* **2017**, 6469138.
- [15] Group A-REDSR (2001) A randomized, placebo-controlled, clinical trial of high-dose supplementation with vitamins C

- and E, beta carotene, and zinc for age-related macular degeneration and vision loss: AREDS report no. 8. *Arch Ophthalmol* **119**, 1417–1436.
- [16] Tomada I & Andrade JP (2015) Science-based anti-ageing nutritional recommendations. In: *Anti-Ageing Nutrients: Evidence Based Prevention Age Associated Diseases*. 1st ed., pp. 333–390 [Neves D, editor]. West Sussex: John Wiley & Sons.
- [17] Armento A, Ueffing M & Clark SJ (2021) The complement system in age-related macular degeneration. *Cell Mol Life Sci* **78**, 4487–4505.
- [18] Walchuk C & Suh M (2020) Nutrition and the aging retina: a comprehensive review of the relationship between nutrients and their role in age-related macular degeneration and retina disease prevention. *Adv Food Nutr Res* **93**, 293–332.
- [19] Hadziahmetovic M & Malek G (2021) Age-related macular degeneration revisited: from pathology and cellular stress to potential therapies. *Front Cell Dev Biol* **8**, 612812.
- [20] Grant MB, Bernstein PS, Boesze-Battaglia K, *et al.* (2022) Inside out: relations between the microbiome, nutrition, and eye health. *Exp Eye Res*, **224**, 109216.
- [21] Rinninella E, Mele MC, Merendino N, *et al.* (2018) The role of diet, micronutrients and the gut microbiota in age-related macular degeneration: new perspectives from the gut–retina axis. *Nutrients* **10**, 1677.
- [22] Di Carlo E & Augustin AJ (2021) Prevention of the onset of age-related macular degeneration. *J Clin Med* **10**, 3297.
- [23] Ferris III FL, Wilkinson C, Bird A, *et al.* (2013) Clinical classification of age-related macular degeneration. *Ophthalmology* **120**, 844–851.
- [24] Klein R, Meuer SM, Myers CE, *et al.* (2014) Harmonizing the classification of age-related macular degeneration in the three-continent AMD consortium. *Ophthalmic Epidemiol* **21**, 14–23.
- [25] Ferris FL, Davis MD, Clemons TE, *et al.* (2005) A simplified severity scale for age-related macular degeneration: AREDS Report No. 18. *Arch Ophthalmol (Chicago, Ill: 1960)* **123**, 1570–1574.
- [26] Bird AC, Bressler NM, Bressler SB, *et al.* (1995) An international classification and grading system for age-related maculopathy and age-related macular degeneration. *Surv Ophthalmol* **39**, 367–374.
- [27] Klaver CC, Assink JJ, van Leeuwen R, *et al.* (2001) Incidence and progression rates of age-related maculopathy: the Rotterdam Study. *Invest Ophthalmol Vis Sci* **42**, 2237–2241.
- [28] Klein R, Davis MD, Magli YL, *et al.* (1991) The Wisconsin age-related maculopathy grading system. *Ophthalmology* **98**, 1128–1134.
- [29] Imamura Y, Noda S, Hashizume K, *et al.* (2006) Drusen, choroidal neovascularization, and retinal pigment epithelium dysfunction in SOD1-deficient mice: a model of age-related macular degeneration. *Proc Natl Acad Sci USA* **103**, 11282–11287.
- [30] Rastoin O, Pagès G & Dufies M (2020) Experimental models in neovascular age related macular degeneration. *Int J Mol Sci* **21**, 4627.
- [31] Lim LS, Mitchell P, Seddon JM, *et al.* (2012) Age-related macular degeneration. *Lancet* **379**, 1728–1738.
- [32] Schaal KB, Rosenfeld PJ, Gregori G, *et al.* (2016) Anatomic clinical trial endpoints for nonexudative age-related macular degeneration. *Ophthalmology* **123**, 1060–1079.
- [33] Schmitz-Valckenberg S, Sadda S, Staurengli G, *et al.* (2016) “Geographic atrophy”: semantic considerations and literature review. *Retina* **36**, 2250.
- [34] Fleckenstein M, Mitchell P, Freund KB, *et al.* (2018) The progression of geographic atrophy secondary to age-related macular degeneration. *Ophthalmology* **125**, 369–390.

- [35] Heesterbeek TJ, Lorés-Motta L, Hoyng CB, *et al.* (2020) Risk factors for progression of age-related macular degeneration. *Ophthalmic Physiol Opt* **40**, 140–170.
- [36] Flaxel CJ, Adelman RA, Bailey ST, *et al.* (2020) Age-related macular degeneration preferred practice pattern®. *Ophthalmology* **127**, P1–P65.
- [37] Chew EY, Clemons TE, SanGiovanni JP, *et al.* (2014) Secondary analyses of the effects of lutein/zeaxanthin on age-related macular degeneration progression: AREDS2 report No. 3. *JAMA Ophthalmol* **132**, 142–149.
- [38] Gorusupudi A, Nelson K & Bernstein PS (2017) The age-related eye disease 2 study: micronutrients in the treatment of macular degeneration. *Adv Nutr* **8**, 40–53.
- [39] Csader S, Korhonen S, Kaamiranta K, *et al.* (2022) The effect of dietary supplementations on delaying the progression of age-related macular degeneration: a systematic review and meta-analysis. *Nutrients* **14**, 4273.
- [40] Seddon JM, Ajani UA, Sperduto RD, *et al.* (1994) Dietary carotenoids, vitamins A, C, and E, and advanced age-related macular degeneration. *JAMA* **272**, 1413–1420.
- [41] Van Leeuwen R, Boekhoorn S, Vingerling JR, *et al.* (2005) Dietary intake of antioxidants and risk of age-related macular degeneration. *JAMA* **294**, 3101–3107.
- [42] Chong EW, Wong TY, Kreis AJ, *et al.* (2007) Dietary antioxidants and primary prevention of age related macular degeneration: systematic review and meta-analysis. *BMJ* **335**, 755.
- [43] Parekh N, Chappell RJ, Millen AE, *et al.* (2007) Association between vitamin D and age-related macular degeneration in the Third National Health and Nutrition Examination Survey, 1988 through 1994. *Arch Ophthalmol* **125**, 661–669.
- [44] Newsome DA (2008) A randomized, prospective, placebo-controlled clinical trial of a novel zinc-monocysteine compound in age-related macular degeneration. *Curr Eye Res* **33**, 591–598.
- [45] Tan JS, Wang JJ, Flood V, *et al.* (2008) Dietary antioxidants and the long-term incidence of age-related macular degeneration: the Blue Mountains Eye Study. *Ophthalmology* **115**, 334–341.
- [46] Christen WG, Glynn RJ, Chew EY, *et al.* (2009) Folic acid, vitamin B6, and vitamin B12 in combination and age-related macular degeneration in a randomized trial of women. *Arch Intern Med* **169**, 335.
- [47] Weigert G, Kaya S, Pemp B, *et al.* (2011) Effects of lutein supplementation on macular pigment optical density and visual acuity in patients with age-related macular degeneration. *Invest Ophthalmol Visual Sci* **52**, 8174–8178.
- [48] Snellen E, Verbeek A, Van Den Hoogen G, *et al.* (2002) Neovascular age-related macular degeneration and its relationship to antioxidant intake. *Acta Ophthalmol Scand* **80**, 368–371.
- [49] Gopinath B, Flood VM, Rochtchina E, *et al.* (2013) Homocysteine, folate, vitamin B-12, and 10-y incidence of age-related macular degeneration. *Am J Clin Nutr* **98**, 129–135.
- [50] Hammond BR, Fletcher LM, Roos F, *et al.* (2014) A double-blind, placebo-controlled study on the effects of lutein and zeaxanthin on photostress recovery, glare disability, and chromatic contrast. *Invest Ophthalmol Vis Sci* **55**, 8583–8589.
- [51] Smailhodzic D, van Asten F, Blom AM, *et al.* (2014) Zinc supplementation inhibits complement activation in age-related macular degeneration. *PLoS One* **9**, e112682.
- [52] Aoki A, Inoue M, Nguyen E, *et al.* (2016) Dietary n-3 fatty acid, α -tocopherol, zinc, vitamin D, vitamin C and β -carotene are associated with age-related macular degeneration in Japan. *Sci Rep* **6**, 20723.
- [53] Braakhuis A, Raman R & Vaghefi E (2017) The association between dietary intake of antioxidants and ocular disease. *Diseases* **5**, 3.
- [54] Merle BM, Silver RE, Rosner B, *et al.* (2017) Associations between vitamin D intake and progression to incident advanced age-related macular degeneration. *Invest Ophthalmol Vis Sci* **58**, 4569–4578.
- [55] Parravano M, Tedeschi M, Manca D, *et al.* (2019) Effects of Macuprev® supplementation in age-related macular degeneration: a double-blind randomized morpho-functional study along 6 months of follow-up. *Adv Ther* **6**, 2493–2505.
- [56] Dave S, Binns A, Vinuela-Navarro V, *et al.* (2022) What advice is currently given to patients with age-related macular degeneration (AMD) by eyecare practitioners, and how effective is it at bringing about a change in lifestyle? A systematic review. *Nutrients* **14**, 4652.
- [57] Parodi MB, Zucchiatti I, Cicinelli MV, *et al.* (2016) Nutritional supplementation in age-related macular degeneration. *Retina* **36**, 1119–1125.
- [58] Awh CC, Lane A-M, Hawken S, *et al.* (2013) CFH and ARMS2 genetic polymorphisms predict response to antioxidants and zinc in patients with age-related macular degeneration. *Ophthalmology* **120**, 2317–2323.
- [59] Alvarez R, Vaz B, Gronemeyer H, *et al.* (2014) Functions, therapeutic applications, and synthesis of retinoids and carotenoids. *Chem Rev* **114**, 1–125.
- [60] Biswal MR, Justis BD, Han P, *et al.* (2018) Daily zeaxanthin supplementation prevents atrophy of the retinal pigment epithelium (RPE) in a mouse model of mitochondrial oxidative stress. *PLoS One* **13**, e0203816.
- [61] Paradowska D & Kucharska E (2020) Nutrition assessment of patients with AMD. *World Sci News* **139**, 221–232.
- [62] Carazo A, Macáková K, Matoušová K, *et al.* (2021) Vitamin A update: forms, sources, kinetics, detection, function, deficiency, therapeutic use and toxicity. *Nutrients* **13**, 1703.
- [63] Sajovic J, Meglič A, Glavač D, *et al.* (2022) The role of vitamin A in retinal diseases. *Int J Mol Sci* **23**, 1014.
- [64] Subczynski WK, Wisniewska A & Widomska J (2010) Location of macular xanthophylls in the most vulnerable regions of photoreceptor outer-segment membranes. *Arch Biochem Biophys* **504**, 61–66.
- [65] Manayi A, Abdollahi M, Raman T, *et al.* (2016) Lutein and cataract: from bench to bedside. *Crit Rev Biotechnol* **36**, 829–839.
- [66] Johra FT, Bepari AK, Bristy AT, *et al.* (2020) A mechanistic review of β -carotene, lutein, and zeaxanthin in eye health and disease. *Antioxidants* **9**, 1046.
- [67] Ranard KM, Jeon S, Mohn ES, *et al.* (2017) Dietary guidance for lutein: consideration for intake recommendations is scientifically supported. *Eur J Nutr* **56**, 37–42.
- [68] Narimatsu T, Negishi K, Miyake S, *et al.* (2015) Blue light-induced inflammatory marker expression in the retinal pigment epithelium-choroid of mice and the protective effect of a yellow intraocular lens material *in vivo*. *Exp Eye Res* **132**, 48–51.
- [69] Mrowicka M, Mrowicki J, Kucharska E, *et al.* (2022) Lutein and zeaxanthin and their roles in age-related macular degeneration—neurodegenerative disease. *Nutrients* **14**, 827.
- [70] Li B, Vachali P & Bernstein PS (2010) Human ocular carotenoid-binding proteins. *Photochem Photobiol Sci* **9**, 1418–1425.
- [71] Hammond BR, Fletcher LM & Elliott JG (2013) Glare disability, photostress recovery, and chromatic contrast: relation to

- macular pigment and serum lutein and zeaxanthin. *Invest Ophthalmol Vis Sci* **54**, 476–481.
- [72] de Koning-Backus AP, Buitendijk GH, Kieft-de Jong JC, *et al.* (2019) Intake of vegetables, fruit, and fish is beneficial for age-related macular degeneration. *Am J Ophthalmol* **198**, 70–79.
- [73] Delcourt C, Cristol J-P, Tessier F, *et al.* (1999) Age-related macular degeneration and antioxidant status in the POLA study. *Arch Ophthalmol* **117**, 1384–1390.
- [74] Huang LL, Coleman HR, Kim J, *et al.* (2008) Oral supplementation of lutein/zeaxanthin and omega-3 long chain polyunsaturated fatty acids in persons aged 60 years or older, with or without AMD. *Invest Ophthalmol Visual Sci* **49**, 3864–3869.
- [75] Ma L, Yan S-F, Huang Y-M, *et al.* (2012) Effect of lutein and zeaxanthin on macular pigment and visual function in patients with early age-related macular degeneration. *Ophthalmology* **119**, 2290–2297.
- [76] Holick MF (2004) Sunlight and vitamin D for bone health and prevention of autoimmune diseases, cancers, and cardiovascular disease. *Am J Clin Nutr* **80**, 1678S–1688S.
- [77] Garcia Layana A, Minnella AM, Garhöfer G, *et al.* (2017) Vitamin D and age-related macular degeneration. *Nutrients* **9**, 1120.
- [78] Morrison MA, Silveira AC, Huynh N, *et al.* (2011) Systems biology-based analysis implicates a novel role for vitamin D metabolism in the pathogenesis of age-related macular degeneration. *Hum Genomics* **5**, 1–31.
- [79] Annweiler C, Drouet M, Duval GT, *et al.* (2016) Circulating vitamin D concentration and age-related macular degeneration: systematic review and meta-analysis. *Maturitas* **88**, 101–112.
- [80] Millen AE, Volland R, Sondel SA, *et al.* (2011) Vitamin D status and early age-related macular degeneration in postmenopausal women. *Arch Ophthalmol* **129**, 481–489.
- [81] Itty S, Day S, Lyles KW, *et al.* (2014) Vitamin D deficiency in neovascular versus nonneovascular age-related macular degeneration. *Retina* **34**, 1779.
- [82] Kabataş N, Doğan AŞ, Yılmaz M, *et al.* (2021) Association between age-related macular degeneration and 25 (OH) vitamin D levels in the Turkish population. *Arq Bras Oftalmol* **85**, 7–12.
- [83] Seddon JM, Reynolds R, Shah HR, *et al.* (2011) Smoking, dietary betaine, methionine, and vitamin D in monozygotic twins with discordant macular degeneration: epigenetic implications. *Ophthalmology* **118**, 1386–1394.
- [84] Jacob J, Mangelschots E, Michez M, *et al.* (2021) Cross-sectional study on vitamin D, zinc oxide and fatty acid status in a population with a moderate to high risk of AMD identified by the STARS® questionnaire. *Ophthalmol Ther* **10**, 299–311.
- [85] Tanito M, Yoshida Y, Kaidzu S, *et al.* (2007) Acceleration of age-related changes in the retina in α -tocopherol transfer protein null mice fed a vitamin E-deficient diet. *Invest Ophthalmol Vis Sci* **48**, 396–404.
- [86] Khoo HE, Ng HS, Yap W-S, *et al.* (2019) Nutrients for prevention of macular degeneration and eye-related diseases. *Antioxidants* **8**, 85.
- [87] Edwards G, Olson CG, Euritt CP, *et al.* (2022) Molecular mechanisms underlying the therapeutic role of vitamin E in age-related macular degeneration. *Front Neurosci* **16**, 890021.
- [88] Akram M, Munir N, Daniyal M, *et al.* (2020) Vitamins and minerals: types, sources and their functions. In: *Functional Foods and Nutraceuticals: Bioactive Compounds Formulations Innovation*. 1st ed. pp. 149–172. [C. Egbuna, G. Dable-Tupas, editor]. Switzerland: Springer Nature.
- [89] Booth SL, Golly I, Sackeck JM, *et al.* (2004) Effect of vitamin E supplementation on vitamin K status in adults with normal coagulation status. *Am J Clin Nutr* **80**, 143–148.
- [90] Klein EA, Thompson IM, Tangen CM, *et al.* (2011) Vitamin E and the risk of prostate cancer: the Selenium and Vitamin E Cancer Prevention Trial (SELECT). *JAMA* **306**, 1549–1556.
- [91] Andreatta W & El-Sherbiny S (2014) Evidence-based nutritional advice for patients affected by age-related macular degeneration. *Ophthalmologica* **231**, 185–190.
- [92] Schmid D, Garhoefer G & Schmetterer L (2015) Nutritional supplements in age-related macular degeneration. *Acta Ophthalmol* **93**, 105–121.
- [93] Parodi MB, Mollo MR, Brunoro A, *et al.* (2018) Micronutrients and benefits of supplementation for reducing the risk of progression of age-related macular degeneration—an update. *J Micronutr Benefits Suppl Reducing Risk Progress Age-Related Macular Degener—An Update* **4**, 780–794.
- [94] Evans JR & Lawrenson JG (2017) Antioxidant vitamin and mineral supplements for preventing age-related macular degeneration. *Cochrane Database Syst Rev* **7**, CD000253.
- [95] Pinna A, Zaccacheddu F, Boscia F, *et al.* (2018) Homocysteine and risk of age-related macular degeneration: a systematic review and meta-analysis. *Acta Ophthalmol* **96**, e269–e276.
- [96] Silverman MD, Tumuluri RJ, Davis M, *et al.* (2002) Homocysteine upregulates vascular cell adhesion molecule-1 expression in cultured human aortic endothelial cells and enhances monocyte adhesion. *Arterioscler Thromb Vasc Biol* **22**, 587–592.
- [97] Fritsche LG, Fariss RN, Stambolian D, *et al.* (2014) Age-related macular degeneration: genetics and biology coming together. *Annu Rev Genom Hum Genet* **15**, 151–171.
- [98] Christen WG, Cook NR, Chiuve SE, *et al.* (2018) Prospective study of plasma homocysteine, its dietary determinants, and risk of age-related macular degeneration in men. *Ophthalmic Epidemiol* **25**, 79–88.
- [99] Gopinath B, Liew G, Russell J, *et al.* (2017) Intake of key micronutrients and food groups in patients with late-stage age-related macular degeneration compared with age–sex-matched controls. *Br J Ophthalmol* **101**, 1027–1031.
- [100] Merle BM, Silver RE, Rosner B, *et al.* (2016) Dietary folate, B vitamins, genetic susceptibility and progression to advanced nonexudative age-related macular degeneration with geographic atrophy: a prospective cohort study. *Am J Clin Nutr* **103**, 1135–1144.
- [101] Kamburoglu G, Gumus K, Kadayıfçılar S, *et al.* (2006) Plasma homocysteine, vitamin B12 and folate levels in age-related macular degeneration. *Graefes Arch Clin Exp Ophthalmol* **244**, 565–569.
- [102] Merle BM, Barthes S, Féart C, *et al.* (2022) B vitamins and incidence of advanced age-related macular degeneration: the Alienor study. *Nutrients* **14**, 2821.
- [103] Prasad AS (2014) Zinc: an antioxidant and anti-inflammatory agent: role of zinc in degenerative disorders of aging. *J Trace Elem Med Biol* **28**, 364–371.
- [104] McCusker MM, Durrani K, Payette MJ, *et al.* (2016) An eye on nutrition: the role of vitamins, essential fatty acids, and antioxidants in age-related macular degeneration, dry eye syndrome, and cataract. *Clin Dermatol* **34**, 276–285.
- [105] Ugarde M & Osborne NN (2014) Recent advances in the understanding of the role of zinc in ocular tissues. *Metallomics* **6**, 189–200.
- [106] Ferrington DA, Ebeling MC, Kapphahn RJ, *et al.* (2017) Altered bioenergetics and enhanced resistance to oxidative stress in human retinal pigment epithelial cells from donors with age-related macular degeneration. *Redox Biol* **13**, 255–265.



- [107] Nan R, Tetchner S, Rodriguez E, *et al.* (2013) Zinc-induced self-association of complement C3b and Factor H: implications for inflammation and age-related macular degeneration. *J Biol Chem* **288**, 19197–19210.
- [108] Vishwanathan R, Chung M & Johnson EJ (2013) A systematic review on zinc for the prevention and treatment of age-related macular degeneration. *Invest Ophthalmol Vis Sci* **54**, 3985–3998.
- [109] Group A-REDSR (2013) Lutein+ zeaxanthin and omega-3 fatty acids for age-related macular degeneration: the Age-Related Eye Disease Study 2 (AREDS2) randomized clinical trial. *JAMA* **309**, 2005–2015.
- [110] Mares JA, Millen AE, Lawler TP, *et al.* (2017) Diet and supplements in the prevention and treatment of eye diseases. In *Nutrition in the prevention and treatment of disease*, pp. 393–434: Elsevier.
- [111] Tsang NC, Penfold PL, Snitch PJ, *et al.* (1992) Serum levels of antioxidants and age-related macular degeneration. *Doc Ophthalmol* **81**, 387–400.
- [112] Group EDCCS (1993) Antioxidant status and neovascular age-related macular degeneration. *Arch Ophthalmol* **111**, 104–109.
- [113] Zampatti S, Ricci F, Cusumano A, *et al.* (2014) Review of nutrient actions on age-related macular degeneration. *Nutr Res* **34**, 95–105.
- [114] Tokarz P, Kaarniranta K & Blasiak J (2013) Role of antioxidant enzymes and small molecular weight antioxidants in the pathogenesis of age-related macular degeneration (AMD). *Biogerontology* **14**, 461–482.
- [115] Seddon JM, Francis PJ, George S, *et al.* (2007) Association of CFH Y402H and LOC387715 A69S with progression of age-related macular degeneration. *JAMA* **297**, 1793–1800.
- [116] Seddon JM, Silver RE & Rosner B (2016) Response to AREDS supplements according to genetic factors: survival analysis approach using the eye as the unit of analysis. *Br J Ophthalmol* **100**, 1731–1737.
- [117] Fritsche LG, Igl W, Bailey JNC, *et al.* (2016) A large genome-wide association study of age-related macular degeneration highlights contributions of rare and common variants. *Nat Genet* **48**, 134–143.
- [118] Fritsche LG, Loenhardt T, Janssen A, *et al.* (2008) Age-related macular degeneration is associated with an unstable ARMS2 (LOC387715) mRNA. *Nat Genet* **40**, 892–896.
- [119] Mukhtar S & Ambati BK (2019) The value of nutritional supplements in treating age-related macular degeneration: a review of the literature. *Int Ophthalmol* **39**, 2975–2983.
- [120] Ho L, van Leeuwen R, Witteman JC, *et al.* (2011) Reducing the genetic risk of age-related macular degeneration with dietary antioxidants, zinc, and ω-3 fatty acids: the Rotterdam study. *Arch Ophthalmol* **129**, 758–766.
- [121] Hammond CJ, Liew SM, Van Kuijk FJ, *et al.* (2012) The heritability of macular response to supplemental lutein and zeaxanthin: a classic twin study. *Invest Ophthalmol Vis Sci* **53**, 4963–4968.
- [122] Meyers KJ, Johnson EJ, Bernstein PS, *et al.* (2013) Genetic determinants of macular pigments in women of the Carotenoids in Age-Related Eye Disease study. *Invest Ophthalmol Vis Sci* **54**, 2333–2345.
- [123] Trvrzicka E, Kremmyda L-S, Stankova B, *et al.* (2011) Fatty acids as biocompounds: their role in human metabolism, health and disease—a review. part 1: classification, dietary sources and biological functions. *Biomed Pap Med Fac Palacky Univ Olomouc* **155**(2), 117–130.
- [124] Tan JS, Wang JJ, Flood V, *et al.* (2009) Dietary fatty acids and the 10-year incidence of age-related macular degeneration: the Blue Mountains Eye Study. *Arch Ophthalmol* **127**, 656–665.
- [125] Smith W, Mitchell P & Leeder SR (2000) Dietary fat and fish intake and age-related maculopathy. *Arch Ophthalmol* **118**, 401–404.
- [126] Cho E, Hung S, Willett WC, *et al.* (2001) Prospective study of dietary fat and the risk of age-related macular degeneration. *Am J Clin Nutr* **73**, 209–218.
- [127] SanGiovanni JP, Chew EY, Clemons TE, *et al.* (2007) The relationship of dietary lipid intake and age-related macular degeneration in a case-control study: AREDS Report No. 20. *Arch Ophthalmol (Chicago, Ill: 1960)* **125**, 671–679.
- [128] Delcourt C, Carrière I, Cristol J-P, *et al.* (2007) Dietary fat and the risk of age-related maculopathy: the POLANUT study. *Eur J Clin Nutr* **61**, 1341–1344.
- [129] Parekh N, Volland RP, Moeller SM, *et al.* (2009) Association between dietary fat intake and age-related macular degeneration in the Carotenoids in Age-Related Eye Disease Study (CAREDS): an ancillary study of the Women's Health Initiative. *Arch Ophthalmol* **127**, 1483–1493.
- [130] Mares-Perlman JA, Brady WE, Klein R, *et al.* (1995) Dietary fat and age-related maculopathy. *Arch Ophthalmol* **113**, 743–748.
- [131] Snow KK & Seddon JM (1999) Do age-related macular degeneration and cardiovascular disease share common antecedents? *Ophthalmic Epidemiol* **6**, 125–143.
- [132] Seddon JM, Cote J & Rosner B (2003) Progression of age-related macular degeneration: association with dietary fat, transunsaturated fat, nuts, and fish intake. *Arch Ophthalmol* **121**, 1728–1737.
- [133] Sasaki M, Harada S, Tsubota K, *et al.* (2020) Dietary saturated fatty acid intake and early age-related macular degeneration in a Japanese population. *Invest Ophthalmol Vis Sci* **61**, 23–23.
- [134] Yasukawa T, Sasaki M, Motomura K, *et al.* (2023) Association between fatty acid intakes and age-related macular degeneration in a Japanese population: JPHC-NEXT eye study. *Trans Vis Sci Techn* **12**, 3.
- [135] Zhong Y, Wang K, Jiang L, *et al.* (2021) Dietary fatty acid intake, plasma fatty acid levels, and the risk of age-related macular degeneration (AMD): a dose–response meta-analysis of prospective cohort studies. *Eur J Nutr*, **60**, 3013–3027.
- [136] Seddon JM, Rosner B, Sperduto RD, *et al.* (2001) Dietary fat and risk for advanced age-related macular degeneration. *Arch Ophthalmol* **119**, 1191–1199.
- [137] Devkota S, Wang Y, Musch MW, *et al.* (2012) Dietary-fat-induced taurocholic acid promotes pathobiont expansion and colitis in *Il10^{-/-}* mice. *Nature* **487**, 104–108.
- [138] Pikuleva IA & Curcio CA (2014) Cholesterol in the retina: the best is yet to come. *Prog Retin Eye Res* **41**, 64–89.
- [139] Klein R, Cruickshanks KJ, Nash SD, *et al.* (2010) The prevalence of age-related macular degeneration and associated risk factors. *Arch Ophthalmol* **128**, 750–758.
- [140] Curcio CA, Johnson M, Huang J-D, *et al.* (2009) Aging, age-related macular degeneration, and the response-to-retention of apolipoprotein B-containing lipoproteins. *Prog Retin Eye Res* **28**, 393–422.
- [141] Curcio CA, Johnson M, Huang J-D, *et al.* (2010) Apolipoprotein B-containing lipoproteins in retinal aging and age-related macular degeneration. *J Lipid Res* **51**, 451–467.
- [142] Hadley D, Orlin A, Brown G, *et al.* (2010) Analysis of six genetic risk factors highly associated with AMD in the region surrounding ARMS2 and HTRA1 on chromosome 10, region q26. *Invest Ophthalmol Vis Sci* **51**, 2191–2196.

- [143] Agrón E, Mares J, Clemons TE, *et al.* (2021) Dietary nutrient intake and progression to late age-related macular degeneration in the age-related eye disease studies 1 and 2. *Ophthalmology* **128**, 425–442.
- [144] Cougnard-Gregoire A, Delyfer M-N, Korobelnik J-F, *et al.* (2014) Elevated high-density lipoprotein cholesterol and age-related macular degeneration: the Alienor study. *PLoS One* **9**, e90973.
- [145] Chong EW-T, Robman LD, Simpson JA, *et al.* (2009) Fat consumption and its association with age-related macular degeneration. *Arch Ophthalmol* **127**, 674–680.
- [146] van Leeuwen EM, Emri E, Merle BM, *et al.* (2018) A new perspective on lipid research in age-related macular degeneration. *Prog Retin Eye Res* **67**, 56–86.
- [147] Cougnard-Gregoire A, Merle BM, Korobelnik J-F, *et al.* (2016) Olive oil consumption and age-related macular degeneration: the ALIENOR Study. *PLoS One* **11**, e0160240.
- [148] Cicerale S, Lucas L, Keast R (2010) Biological activities of phenolic compounds present in virgin olive oil. *Int J Mol Sci* **11**, 458–479.
- [149] Parkinson L & Keast R (2014) Oleocanthal, a phenolic derived from virgin olive oil: a review of the beneficial effects on inflammatory disease. *Int J Mol Sci* **15**, 12323–12334.
- [150] Castaner O, Covas M-I, Khymenets O, *et al.* (2012) Protection of LDL from oxidation by olive oil polyphenols is associated with a downregulation of CD40-ligand expression and its downstream products *in vivo* in humans. *Am J Clin Nutr* **95**, 1238–1244.
- [151] Lockyer S & Rowland I (2014) Authorised EU health claims for polyphenols in olive oil. In *Foods, nutrients and food ingredients with authorised EU health claims*, pp. 212–228. [MJ Sadler, editor] Cambridge: Woodhead Publishing.
- [152] Zhu L, Liu Z, Feng Z, *et al.* (2010) Hydroxytyrosol protects against oxidative damage by simultaneous activation of mitochondrial biogenesis and phase II detoxifying enzyme systems in retinal pigment epithelial cells. *J Nutr Biochem* **21**, 1089–1098.
- [153] Saini RK & Keum Y-S (2018) Omega-3 and omega-6 polyunsaturated fatty acids: dietary sources, metabolism, and significance—a review. *Life Sci* **203**, 255–267.
- [154] Djuricic I & Calder PC (2021) Beneficial outcomes of omega-6 and omega-3 polyunsaturated fatty acids on human health: an update for 2021. *Nutrients* **13**, 2421.
- [155] Khandhadia S & Lotery A (2010) Oxidation and age-related macular degeneration: insights from molecular biology. *Expert Rev Mol Med* **12**, e34.
- [156] Abokyi S, To C-H, Lam TT, *et al.* (2020) Central role of oxidative stress in age-related macular degeneration: evidence from a review of the molecular mechanisms and animal models. *Oxid Med Cell Longev* **2020**, 7901270.
- [157] Fan H & Song J-T (2022) Potential mechanisms of macular degeneration protection by fatty fish consumption. *Curr Opin Pharmacol* **63**, 102186.
- [158] Wu J, Cho E, Giovannucci EL, *et al.* (2017) Dietary intakes of eicosapentaenoic acid and docosahexaenoic acid and risk of age-related macular degeneration. *Ophthalmology* **124**, 634–643.
- [159] Chong EW, Kreis AJ, Wong TY, *et al.* (2008) Dietary ω -3 fatty acid and fish intake in the primary prevention of age-related macular degeneration: a systematic review and meta-analysis. *Arch Ophthalmol* **126**, 826–833.
- [160] Jiang H, Shi X, Fan Y, *et al.* (2021) Dietary omega-3 polyunsaturated fatty acids and fish intake and risk of age-related macular degeneration. *Clin Nutr* **40**, 5662–5673.
- [161] SanGiovanni JP, Agron E, Meleth AD, *et al.* (2009) ω -3 Long-chain polyunsaturated fatty acid intake and 12-y incidence of neovascular age-related macular degeneration and central geographic atrophy: a prospective cohort study from the age-related eye disease study. *Am J Clin Nutr* Published Ahead of print Oct 7.
- [162] SanGiovanni JP, Chew EY, Agron E, *et al.* (2008) The relationship of dietary ω -3 long-chain polyunsaturated fatty acid intake with incident age-related macular degeneration: AREDS report no. 23. *Arch Ophthalmol* **126**, 1274–1279.
- [163] Gil A & Gil F (2015) Fish, a Mediterranean source of *n*-3 PUFA: benefits do not justify limiting consumption. *Br J Nutr* **113**, S58–S67.
- [164] Christen WG, Schaumberg DA, Glynn RJ, *et al.* (2011) Dietary ω -3 fatty acid and fish intake and incident age-related macular degeneration in women. *Arch Ophthalmol* **129**, 921–929.
- [165] Swenor BK, Bressler S, Caulfield L, *et al.* (2010) The impact of fish and shellfish consumption on age-related macular degeneration. *Ophthalmology* **117**, 2395–2401.
- [166] Heuberger RA, Mares-Perlman JA, Klein R, *et al.* (2001) Relationship of dietary fat to age-related maculopathy in the Third National Health and Nutrition Examination Survey. *Arch Ophthalmol* **119**, 1833–1838.
- [167] Dinu M, Pagliai G, Casini A, *et al.* (2019) Food groups and risk of age-related macular degeneration: a systematic review with meta-analysis. *Eur J Nutr* **58**, 2123–2143.
- [168] Liput KP, Lepczyński A, Ogluszka M, *et al.* (2021) Effects of dietary *n*-3 and *n*-6 polyunsaturated fatty acids in inflammation and cancerogenesis. *Int J Mol Sci* **22**, 6965.
- [169] Čaljušić Mance T, Kovačević D, Alpeza-Dunato Z, *et al.* (2011) The role of omega6 to omega3 ratio in development and progression of age-related macular degeneration. *Coll Antropol* **35**, 307–310.
- [170] Serhan CN (2007) Resolution phase of inflammation: novel endogenous anti-inflammatory and proresolving lipid mediators and pathways. *Annu Rev Immunol* **25**, 101–137.
- [171] Shinto L, Marracci G, Bumgarner L, *et al.* (2011) The effects of omega-3 fatty acids on matrix metalloproteinase-9 production and cell migration in human immune cells: implications for multiple sclerosis. *Autoimmune Dis* **2011**, 134592.
- [172] Fu Z, Liegl R, Wang Z, *et al.* (2017) Adiponectin mediates dietary omega-3 long-chain polyunsaturated fatty acid protection against choroidal neovascularization in mice. *Invest Ophthalmol Vis Sci* **58**, 3862–3870.
- [173] Johansson I, Monsen VT, Pettersen K, *et al.* (2015) The marine *n*-3 PUFA DHA evokes cytoprotection against oxidative stress and protein misfolding by inducing autophagy and NFE2L2 in human retinal pigment epithelial cells. *Autophagy* **11**, 1636–1651.
- [174] SanGiovanni JP & Chew EY (2005) The role of omega-3 long-chain polyunsaturated fatty acids in health and disease of the retina. *Prog Retin Eye Res* **24**, 87–138.
- [175] Reynolds R, Rosner B & Seddon JM (2013) Dietary omega-3 fatty acids, other fat intake, genetic susceptibility, and progression to incident geographic atrophy. *Ophthalmology* **120**, 1020–1028.
- [176] Wang JJ, Rochtchina E, Smith W, *et al.* (2009) Combined effects of complement factor H genotypes, fish consumption, and inflammatory markers on long-term risk for age-related macular degeneration in a cohort. *Am J Epidemiol* **169**, 633–641.
- [177] Jenkins DJ, Wolever T, Taylor RH, *et al.* (1981) Glycemic index of foods: a physiological basis for carbohydrate exchange. *Am J Clin Nutrition* **34**, 362–366.
- [178] Wolever TM, Jenkins D, Jenkins AL, *et al.* (1991) The glycemic index: methodology and clinical implications. *Am J Clin Nutr* **54**, 846–854.

- [179] Kumagai AK (1999) Glucose transport in brain and retina: implications in the management and complications of diabetes. *Diabetes Metab Res Rev* **15**, 261–273.
- [180] Stitt AW (2005) The Maillard reaction in eye diseases. *Ann NY Acad Sci* **1043**, 582–597.
- [181] Kearney FM, Fagan XJ & Al-Qureshi S (2014) Review of the role of refined dietary sugars (fructose and glucose) in the genesis of retinal disease. *Clin Exp Ophthalmol* **42**, 564–573.
- [182] Stitt AW (2001) Advanced glycation: an important pathological event in diabetic and age related ocular disease. *Br J Ophthalmol* **85**, 746–753.
- [183] Chiu C-J, Milton RC, Gensler G, *et al.* (2006) Dietary carbohydrate intake and glycemic index in relation to cortical and nuclear lens opacities in the age-related eye disease study. *Am J Clin Nutr* **83**, 1177–1184.
- [184] Chiu CJ, Morris M, Hubbard L, *et al.* (2005) Dietary glycemic index and carbohydrate intake in relation to early age-related maculopathy. *Invest Ophthalmol Vis Sci* **46**, 3300–3300.
- [185] Chiu C-J, Milton RC, Gensler G, *et al.* (2007) Association between dietary glycemic index and age-related macular degeneration in nondiabetic participants in the age-related eye disease study. *Am J Clin Nutr* **86**, 180–188.
- [186] Kaushik S, Wang JJ, Flood V, *et al.* (2008) Dietary glycemic index and the risk of age-related macular degeneration. *Am J Clin Nutr* **88**, 1104–1110.
- [187] Movahedian M, Thomas J, Rahmani J, *et al.* (2020) Association between dietary glycemic index and glycemic load, insulin index and load with incidence of age-related cataract: results from a case-control study. *Diabetes Metab Syndr: Clin Res Rev* **14**, 199–204.
- [188] Rowan S, Jiang S, Chang M-L, *et al.* (2020) A low glycemic diet protects disease-prone Nrf2-deficient mice against age-related macular degeneration. *Free Rad Biol Med* **150**, 75–86.
- [189] Rowan S, Jiang S, Korem T, *et al.* (2017) Involvement of a gut-retina axis in protection against dietary glycemia-induced age-related macular degeneration. *Proc Natl Acad Sci USA* **114**, E4472–E4481.
- [190] Champ M, Langkilde A-M, Brouns F, *et al.* (2003) Advances in dietary fibre characterisation. 1. Definition of dietary fibre, physiological relevance, health benefits and analytical aspects. *Nutr Res Rev* **16**, 71–82.
- [191] Soliman GA (2019) Dietary fiber, atherosclerosis, and cardiovascular disease. *Nutrients* **11**, 1155.
- [192] Macfarlane GT & Macfarlane S (2012) Bacteria, colonic fermentation, and gastrointestinal health. *JAOAC Int* **95**, 50–60.
- [193] Andriessen EM, Wilson AM, Mawambo G, *et al.* (2016) Gut microbiota influences pathological angiogenesis in obesity-driven choroidal neovascularization. *EMBO Mol Med* **8**, 1366–1379.
- [194] Tinkilic Ş, Aksoydan E, Çitrik M, *et al.* (2022) Evaluation of nutritional status of the individuals with age-related macular degeneration (AMD). *Nutrire* **47**, 4.
- [195] Mares-Perlman JA, Brady WE, Klein BE, *et al.* (1995) Diet and nuclear lens opacities. *Am J Epidemiol* **141**, 322–334.
- [196] Townend BS, Townend ME, Flood V, *et al.* (2007) Dietary macronutrient intake and five-year incident cataract: the Blue Mountains Eye Study. *Am J Ophthalmol* **143**, 932–939. e931.
- [197] Pameijer EM, Heus P, Damen JA, *et al.* (2022) What did we learn in 35 years of research on nutrition and supplements for age-related macular degeneration: a systematic review. *Acta Ophthalmol* **100**, e1541–e1552.
- [198] Bosch-Morell F, Villagrana V, Ortega T, *et al.* (2020) Medicinal plants and natural products as neuroprotective agents in age-related macular degeneration. *Neural Regen Res* **15**, 2207–2216.
- [199] Bungau S, Abdel-Daim MM, Tit DM, *et al.* (2019) Health benefits of polyphenols and carotenoids in age-related eye diseases. *Oxid Med Cell Longev* **2019**, 9783429.
- [200] Lem DW, Gierhart DL & Davey PG (2021) A Systematic review of carotenoids in the management of diabetic retinopathy. *Nutrients* **13**, 1–23.
- [201] Manikandan R, Thiagarajan R, Goutham G, *et al.* (2016) Zeaxanthin and ocular health, from bench to bedside. *Fitoterapia* **109**, 58–66.
- [202] Merle BMJ, Rosner B & Seddon JM (2020) Genetic susceptibility, diet quality, and two-step progression in drusen size. *Invest Ophthalmol Vis Sci* **61**, 17.
- [203] Pawlowska E, Szczepanska J, Koskela A, *et al.* (2019) Dietary polyphenols in age-related macular degeneration: protection against oxidative stress and beyond. *Oxid Med Cell Longev* **2019**, 9682318.
- [204] Kim EK, Kim H, Kwon O, *et al.* (2018) Associations between fruits, vegetables, vitamin A, beta-carotene and flavonol dietary intake, and age-related macular degeneration in elderly women in Korea: the Fifth Korea National Health and Nutrition Examination Survey. *Eur J Clin Nutr* **72**, 161–167.
- [205] Baur JA & Sinclair DA (2006) Therapeutic potential of resveratrol: the *in vivo* evidence. *Nat Rev Drug Discov* **5**, 493–506.
- [206] Abu-Amero KK, Kondkar AA & Chalam KV (2016) Resveratrol and ophthalmic diseases. *Nutrients* **8**, 200.
- [207] Alaïmo A, Di Santo MC, Dominguez Rubio AP, *et al.* (2020) Toxic effects of A2E in human ARPE-19 cells were prevented by resveratrol: a potential nutritional bioactive for age-related macular degeneration treatment. *Arch Toxicol* **94**, 553–572.
- [208] Sheu S-J, Liu N-C, Ou C-C, *et al.* (2013) Resveratrol stimulates mitochondrial bioenergetics to protect retinal pigment epithelial cells from oxidative damage. *Invest Ophthalmol Vis Sci* **54**, 6426–6438.
- [209] Richer S, Patel S, Sockanathan S, *et al.* (2014) Resveratrol based oral nutritional supplement produces long-term beneficial effects on structure and visual function in human patients. *Nutrients* **6**, 4404–4420.
- [210] King RE, Kent KD & Bomser JA (2005) Resveratrol reduces oxidation and proliferation of human retinal pigment epithelial cells via extracellular signal-regulated kinase inhibition. *Chem Biol Interact* **151**, 143–149.
- [211] Zheng T & Lu Y (2016) SIRT1 protects human lens epithelial cells against oxidative stress by inhibiting p53-dependent apoptosis. *Curr Eye Res* **41**, 1068–1075.
- [212] Luna C, Li G, Liton PB, *et al.* (2009) Resveratrol prevents the expression of glaucoma markers induced by chronic oxidative stress in trabecular meshwork cells. *Food Chem Toxicol* **47**, 198–204.
- [213] Kubota S, Kurihara T, Ebinuma M, *et al.* (2010) Resveratrol prevents light-induced retinal degeneration via suppressing activator protein-1 activation. *Am J Pathol* **177**, 1725–1731.
- [214] Anekonda TS & Adamus G (2008) Resveratrol prevents antibody-induced apoptotic death of retinal cells through upregulation of Sirt1 and Ku70. *BMC Res Notes* **1**, 1–8.
- [215] Pintea A, Rugină D, Pop R, *et al.* (2011) Antioxidant effect of trans-resveratrol in cultured human retinal pigment epithelial cells. *J Ocul Pharmacol Ther* **27**, 315–321.
- [216] Chung S, Yao H, Caito S, *et al.* (2010) Regulation of SIRT1 in cellular functions: role of polyphenols. *Arch Biochem Biophys* **501**, 79–90.
- [217] Gopinath B, Liew G, Kifley A, *et al.* (2018) Dietary flavonoids and the prevalence and 15-y incidence of age-related macular degeneration. *Am J Clin Nutr* **108**, 381–387.

- [218] Sin HP, Liu DT & Lam DS (2013) Lifestyle modification, nutritional and vitamins supplements for age-related macular degeneration. *Acta Ophthalmol* **91**, 6–11.
- [219] Khoo HE, Azlan A, Tang ST, *et al.* (2017) Anthocyanidins and anthocyanins: colored pigments as food, pharmaceutical ingredients, and the potential health benefits. *Food Nutr Res* **61**, 1361779.
- [220] Paik S-S, Jeong E, Jung SW, *et al.* (2012) Anthocyanins from the seed coat of black soybean reduce retinal degeneration induced by *N*-methyl-*N*-nitrosourea. *Exp Eye Res* **97**, 55–62.
- [221] Jang YP, Zhou J, Nakanishi K, *et al.* (2005) Anthocyanins protect against A2E photooxidation and membrane permeabilization in retinal pigment epithelial cells. *Photochem Photobiol* **81**, 529–536.
- [222] Wang Y, Zhao L, Wang C, *et al.* (2017) Protective effect of quercetin and chlorogenic acid, two polyphenols widely present in edible plant varieties, on visible light-induced retinal degeneration *in vivo*. *J Funct Foods* **33**, 103–111.
- [223] Cao X, Liu M, Tuo J, *et al.* (2010) The effects of quercetin in cultured human RPE cells under oxidative stress and in *Ccl2/Cx3cr1* double deficient mice. *Exp Eye Res* **91**, 15–25.
- [224] Lashay A, Sadough G, Ashrafi E, *et al.* (2016) Short-term outcomes of saffron supplementation in patients with age-related macular degeneration: a double-blind, placebo-controlled, randomized trial. *Med Hypothesis Discov Innov Ophthalmol* **5**, 32–38.
- [225] Di Marco S, Carnicelli V, Franceschini N, *et al.* (2019) Saffron: a multitask neuroprotective agent for retinal degenerative diseases. *Antioxidants* **8**, 224.
- [226] Spadiene A, Savickiene N, Jurgevicene N, *et al.* (2013) Effect of ginkgo extract on eye microcirculation in patients with diabetes. *Open Med* **8**, 736–741.
- [227] Huang WY, Wu H, Li DJ, *et al.* (2018) Protective effects of blueberry anthocyanins against H₂O₂-induced oxidative injuries in human retinal pigment epithelial cells. *J Agric Food Chem* **66**, 1638–1648.
- [228] Osada H, Okamoto T, Kawashima H, *et al.* (2017) Neuroprotective effect of bilberry extract in a murine model of photo-stressed retina. *PLoS One* **12**, e0178627.
- [229] Li X, Holt RR, Keen CL, *et al.* (2021) Goji berry intake increases macular pigment optical density in healthy adults: a randomized pilot trial. *Nutrients* **13**, 449.
- [230] Park SI, Lee EH, Kim SR, *et al.* (2017) Anti-apoptotic effects of *Curcuma longa* L. extract and its curcuminoids against blue light-induced cytotoxicity in A2E-laden human retinal pigment epithelial cells. *J Pharm Pharmacol* **69**, 334–340.
- [231] Jitsanong T, Khanobdee K, Piyachaturawat P, *et al.* (2011) Diarylheptanoid 7-(3,4 dihydroxyphenyl)-5-hydroxy-1-phenyl-(1*E*)-1-heptene from *Curcuma comosa* Roxb. protects retinal pigment epithelial cells against oxidative stress-induced cell death. *Toxicol In Vitro* **25**, 167–176.
- [232] Hills Jr RD, Pontefract BA, Mishcon HR, *et al.* (2019) Gut microbiome: profound implications for diet and disease. *Nutrients* **11**, 1613.
- [233] Napolitano P, Filippelli M, Davinelli S, *et al.* (2021) Influence of gut microbiota on eye diseases: an overview. *Ann Med* **53**, 750–761.
- [234] Zisimopoulos A, Klavdianou O, Theodossiadis P, *et al.* (2021) The role of the microbiome in age-related macular degeneration: a review of the literature. *Ophthalmologica* **244**, 173–178.
- [235] Andriessen EM, Wilson AM, Mawambo G, *et al.* (2016) Gut microbiota influences pathological angiogenesis in obesity-driven choroidal neovascularization. *EMBO Mol Med* **8**, 1366–1379.
- [236] Rowan S & Taylor A (2018) Gut microbiota modify risk for dietary glycemia-induced age-related macular degeneration. *Gut Microbes* **9**, 452–457.
- [237] Zinkernagel MS, Zysset-Burri DC, Keller I, *et al.* (2017) Association of the intestinal microbiome with the development of neovascular age-related macular degeneration. *Sci Rep* **7**, 40826.
- [238] Zysset-Burri DC, Keller I, Berger LE, *et al.* (2020) Associations of the intestinal microbiome with the complement system in neovascular age-related macular degeneration. *NPJ Genom Med* **5**, 34.
- [239] Bui BV, Hu RG, Acosta ML, *et al.* (2009) Glutamate metabolic pathways and retinal function. *J Neurochem* **111**, 589–599.
- [240] Zysset-Burri DC, Morandi S, Herzog EL, *et al.* (2023) The role of the gut microbiome in eye diseases. *Prog Retin Eye Res* **92**, 101117.
- [241] Singh RK, Chang H-W, Yan D, *et al.* (2017) Influence of diet on the gut microbiome and implications for human health. *J Trans Med* **15**, 1–17.
- [242] Francisco SG, Smith KM, Aragonés G, *et al.* (2020) Dietary patterns, carbohydrates, and age-related eye diseases. *Nutrients* **12**, 2862.
- [243] Lin P (2018) The role of the intestinal microbiome in ocular inflammatory disease. *Curr Opin Ophthalmol* **29**, 261–266.
- [244] Floyd JL & Grant MB (2020) The gut–eye axis: lessons learned from murine models. *Ophthalmol Ther* **9**, 499–513.
- [245] Xiao J, Xie B, Dao D, *et al.* (2022) High-fat diet alters the retinal pigment epithelium and choroidal transcriptome in the absence of gut microbiota. *Cells* **11**, 2076.
- [246] Jefferson A & Adolphus K (2019) The effects of intact cereal grain fibers, including wheat bran on the gut microbiota composition of healthy adults: a systematic review. *Front Nutr* **6**, 33.
- [247] Gamage H, Tetu SG, Chong RWW, *et al.* (2017) Cereal products derived from wheat, sorghum, rice and oats alter the infant gut microbiota *in vitro*. *Sci Rep* **7**, 14312.
- [248] Berding K, Carbia C & Cryan JF (2021) Going with the grain: fiber, cognition, and the microbiota-gut-brain-axis. *Exp Biol Med* **246**, 796–811.
- [249] Loo YT, Howell K, Chan M, *et al.* (2020) Modulation of the human gut microbiota by phenolics and phenolic fiber-rich foods. *Compr Rev Food Sci Food Saf* **19**, 1268–1298.
- [250] Hervert Hernández D (2021) Gut microbiota and grain fiber: evidence and practical recommendations. *Nutr Hosp* **38**, 13–16.
- [251] Parolini C (2019) Effects of fish *n*-3 PUFAs on intestinal microbiota and immune system. *Mar Drugs* **17**, 374.
- [252] Andersen AD, Mølbak L, Michaelsen KF, *et al.* (2011) Molecular fingerprints of the human fecal microbiota from 9 to 18 months old and the effect of fish oil supplementation. *J Pediatr Gastroenterol Nutr* **3**, 303–309.
- [253] Farajipour H, Sadr S, Matin HR, *et al.* (2023) Therapeutic effect of probiotics on metabolic indices and clinical signs in age-related macular degeneration. *J Immunoassay Immunobchem* **44**, 229–241.
- [254] Morita Y, Miwa Y, Jounai K, *et al.* (2018) *Lactobacillus paracasei* KW3110 prevents blue light-induced inflammation and degeneration in the retina. *Nutrients* **10**, 1991.
- [255] Choi EY, Kim M, Lee CS, *et al.* (2022) Intermittent fasting is associated with a decreased risk of age-related macular degeneration. *Am J Ophthalmol* **243**, 1–9.
- [256] Hogg RE & Woodside JV (2019) Mediterranean diet and age-related macular degeneration: is it time to attempt dietary modification? *Ophthalmology* **126**, 391–392.

- [257] Gastaldello A, Giampieri F, Quiles JL, *et al.* (2022) Adherence to the Mediterranean-style eating pattern and macular degeneration: a systematic review of observational studies. *Nutrients* **14**, 2028.
- [258] Hogg RE, Woodside JV, McGrath A, *et al.* (2017) Mediterranean diet score and its association with age-related macular degeneration: the European eye study. *Ophthalmology* **124**, 82–89.
- [259] Raimundo M, Mira F, Cachulo MDL, *et al.* (2018) Adherence to a Mediterranean diet, lifestyle and age-related macular degeneration: the Coimbra Eye Study – report 3. *Acta Ophthalmol* **96**, e926–e932.
- [260] Kang KT & Kim YC (2019) Dietary patterns and age-related Macular degeneration in Korea: the Korea National Health and Nutrition Examination Survey 2010–2011. *Sci Rep* **9**, 8200.
- [261] Sasaki M, Miyagawa N, Harada S, *et al.* (2022) Dietary patterns and their associations with intermediate age-related macular degeneration in a Japanese population. *J Clin Med* **11**, 1617.
- [262] Chiu CJ, Chang ML, Li T, *et al.* (2017) Visualization of dietary patterns and their associations with age-related macular degeneration. *Invest Ophthalmol Vis Sci* **58**, 1404–1410.
- [263] Amirul Islam FM, Chong EW, Hodge AM, *et al.* (2014) Dietary patterns and their associations with age-related macular degeneration: the Melbourne collaborative cohort study. *Ophthalmology* **121**, 1428–1434 e1422.
- [264] Nunes S, Alves D, Barreto P, *et al.* (2018) Adherence to a Mediterranean diet and its association with age-related macular degeneration. The Coimbra Eye Study-Report 4. *Nutrition* **51–52**, 6–12.
- [265] Kim EK, Kim H, Vijayakumar A, *et al.* (2017) Associations between fruit and vegetable, and antioxidant nutrient intake and age-related macular degeneration by smoking status in elderly Korean men. *Nutr J* **16**, 77.
- [266] Tang D, Mitchell P, Flood V, *et al.* (2019) Dietary intervention in patients with age-related macular degeneration: protocol for a randomised controlled trial. *BMJ Open* **9**, e024774.
- [267] Dighe S, Zhao J, Steffen L, *et al.* (2020) Diet patterns and the incidence of age-related macular degeneration in the Atherosclerosis Risk in Communities (ARIC) study. *Br J Ophthalmol* **104**, 1070–1076.
- [268] McCarter RV, Neville CE, Silvestri G, *et al.* (2019) Dietary patterns were not associated with age-related macular degeneration: a cross-sectional analysis in the Irish Nun Eye Study. *Ir J Med Sci* **188**, 1005–1012.
- [269] Montgomery MP, Kamel F, Pericak-Vance MA, *et al.* (2010) Overall diet quality and age-related macular degeneration. *Ophthalmic Epidemiol* **17**, 58–65.
- [270] Merle BM, Colijn JM, Cougnard-Grégoire A, *et al.* (2019) Mediterranean diet and incidence of advanced age-related macular degeneration: the EYE-RISK Consortium. *Ophthalmology* **126**, 381–390.
- [271] Merle BM, Silver RE, Rosner B, *et al.* (2015) Adherence to a Mediterranean diet, genetic susceptibility, and progression to advanced macular degeneration: a prospective cohort study. *Am J Clin Nutr* **102**, 1196–1206.
- [272] Keenan TD, Agron E, Mares J, *et al.* (2020) Adherence to the Mediterranean diet and progression to late age-related macular degeneration in the age-related eye disease studies 1 and 2. *Ophthalmology* **127**, 1515–1528.
- [273] Merle BMJ, Cougnard-Grégoire A, Korobelnik JF, *et al.* (2021) Plasma Lutein, a nutritional biomarker for development of advanced age-related macular degeneration: the Alienor Study. *Nutrients* **13**, 2047.
- [274] Loo YT, Howell K, Chan M, *et al.* (2020) Modulation of the human gut microbiota by phenolics and phenolic fiber-rich foods. *Compr Rev Food Sci Food Saf* **19**, 1268–1298.
- [275] Martín-Peláez S, Covas MI, Fito M, *et al.* (2013) Health effects of olive oil polyphenols: recent advances and possibilities for the use of health claims. *Mol Nutr Food Res* **57**, 760–771.
- [276] Merle BM, Buaud B, Korobelnik JF, *et al.* (2017) Plasma long-chain omega-3 polyunsaturated fatty acids and macular pigment in subjects with family history of age-related macular degeneration: the Limpia Study. *Acta Ophthalmol* **95**, 763–769.
- [277] Chiu C-J, Milton RC, Klein R, *et al.* (2007) Dietary carbohydrate and the progression of age-related macular degeneration: a prospective study from the Age-Related Eye Disease Study. *Am J Clin Nutr* **86**, 1210–1218.
- [278] Obin M, Pike A, Halbleib M, *et al.* (2000) Calorie restriction modulates age-dependent changes in the retinas of Brown Norway rats. *Mech Ageing Dev* **114**, 133–147.
- [279] Obin M, Halbleib M, Lipman R, *et al.* (2000) Calorie restriction increases light-dependent photoreceptor cell loss in the neural retina of Fischer 344 rats. *Neurobiol Aging* **21**, 639–645.
- [280] Katz ML, White HA, Gao CL, *et al.* (1993) Dietary restriction slows age pigment accumulation in the retinal pigment epithelium. *Invest Ophthalmol Vis Sci* **34**, 3297–3302.
- [281] Guo X, Kimura A, Azuchi Y, *et al.* (2016) Caloric restriction promotes cell survival in a mouse model of normal tension glaucoma. *Sci Rep* **6**, 1–10.
- [282] Kong YXG, van Bergen N, Bui BV, *et al.* (2012) Impact of aging and diet restriction on retinal function during and after acute intraocular pressure injury. *Neurobiol Aging* **33**, 1126.e1115–1126. e1125.